

Regional Anesthesia Workshop

Table of Contents

I. Upper extremity neuroanatomy.....	page 3
II. Upper extremity regional techniques.....	page 5
III. Lower extremity neuroanatomy.....	page 13
IV. Lower extremity regional techniques.....	page 16
V. Truncal neuroanatomy and regional techniques.....	page 26
VI. Suggested reading.....	page 29

I. Upper Extremity Neuroanatomy

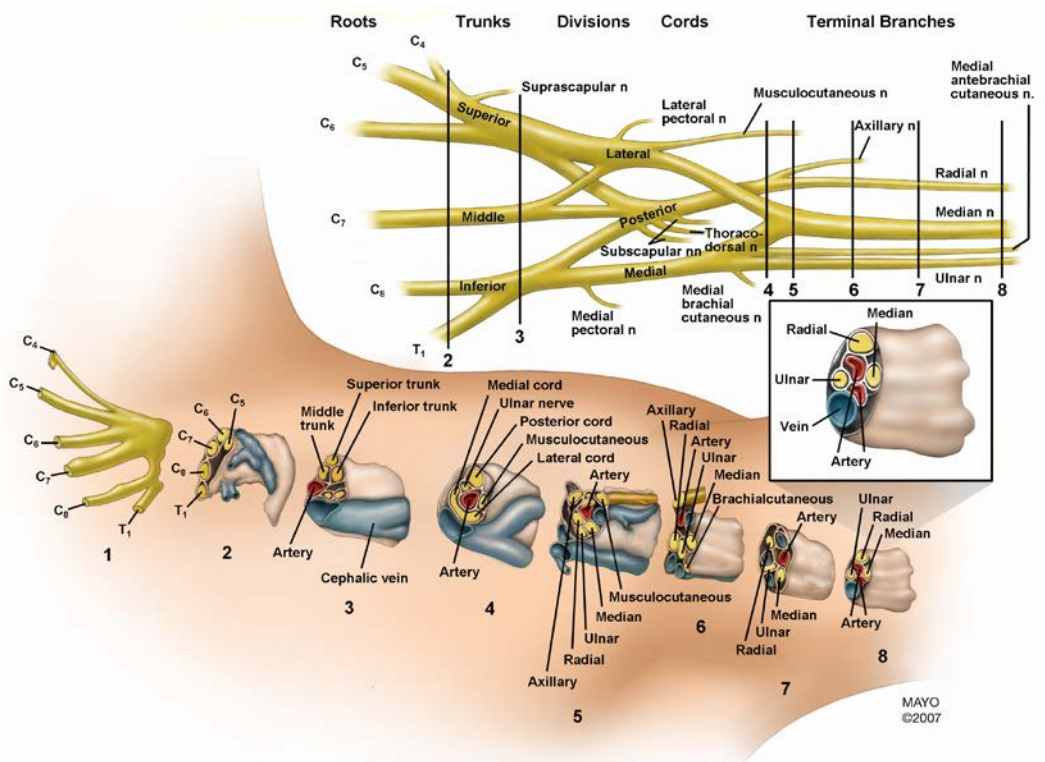


Figure 1. *Brachial plexus*

Roots: Anterior (ventral) rami of C5 - T1 (variable contributions from C4 and T1)

Trunks: Form at the lateral border of the middle scalene muscle

- *Superior trunk:* formed from C5 and C6
- *Middle trunk:* formed from C7
- *Inferior trunk:* formed from C8 and T1

Divisions: All trunks separate into an anterior and posterior division at the lateral border of the 1st rib (above & behind the middle 3rd of the clavicle)

- *Anterior divisions:* supply the ventral (flexor) portion of the extremity
- *Posterior divisions:* supply the dorsal (extensor) portion of the extremity

Cords: Form at the apex of the axilla and named according to their relationship to the second part of the axillary artery (posterior to the pectoralis minor).

- *Lateral cord:* formed from anterior divisions of the superior and middle trunks
- *Posterior cord:* formed from the posterior divisions of all three trunks
- *Medial cord:* formed from the anterior division of the inferior trunk

Terminal Branches: Form at the lateral border of the pectoralis minor

- Lateral cord has two major terminal branches
 1. Musculocutaneous nerve (supplies biceps and terminates as lateral antebrachial cutaneous nerve of the forearm)
 2. Median nerve (lateral root)
- Posterior Cord has two major terminal branches
 1. Axillary nerve (supplies deltoid and cutaneous skin innervation over lateral shoulder)
 2. Radial nerve
- Medial Cord has three major terminal branches
 1. Ulnar nerve
 2. Median nerve (medial root)
 3. Medial antebrachial cutaneous nerve of the forearm (medial forearm)
 4. Medial cutaneous nerve of the arm (medial aspect of upper arm)

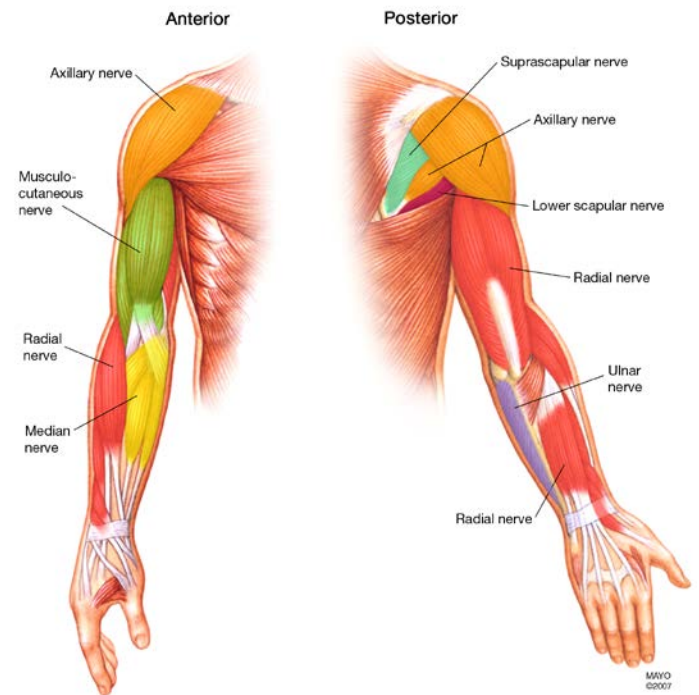
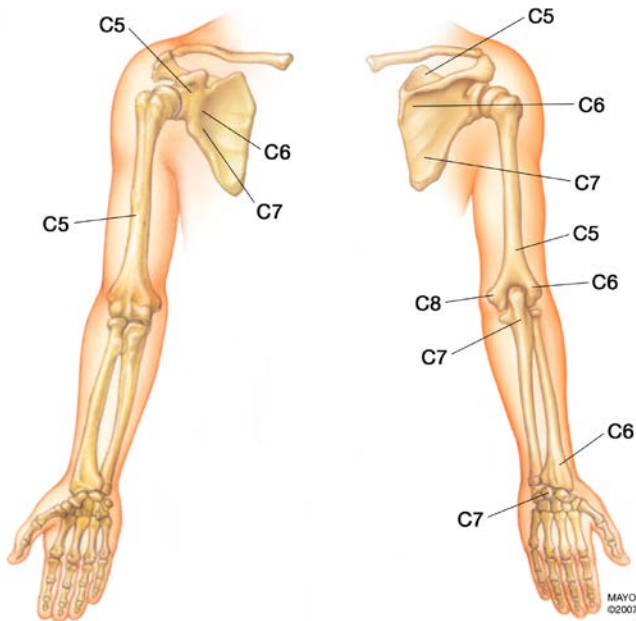
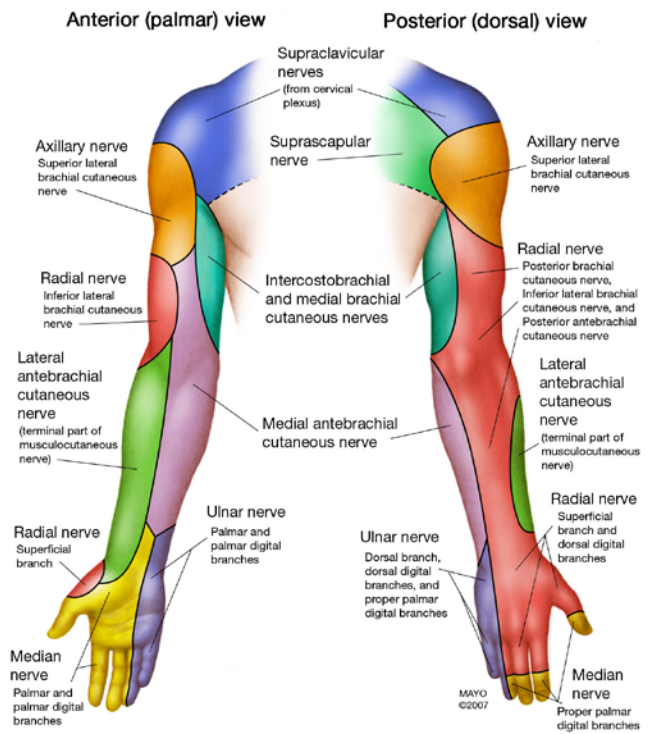
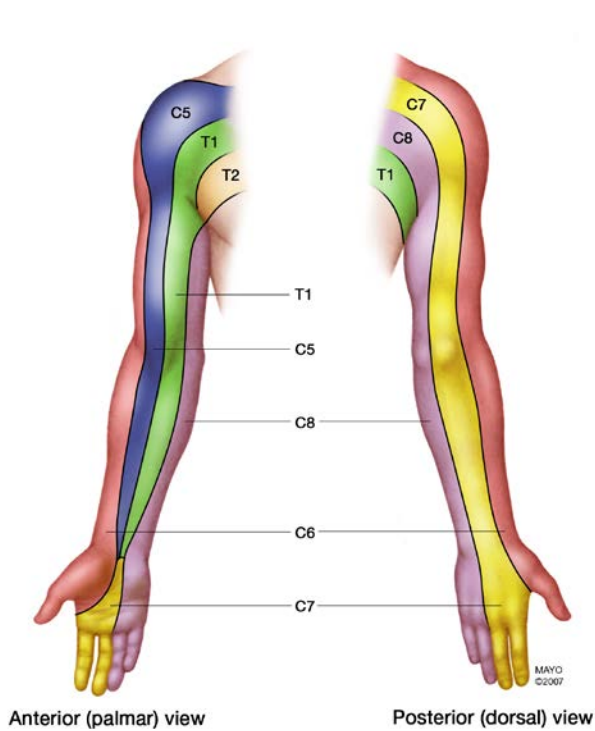


Figure 2. Upper extremity innervation (dermatomes, osteotomes, myotomes)

II. Upper Extremity Regional Techniques

A. INTERSCALENE BLOCKADE

- Indication: Surgery of the shoulder or upper arm
- Level of blockade: Distal roots to proximal trunks
- Limitations:
 1. Sparing of C8 & T1 nerve function (ulnar n. failure rate ~ 25%)
 2. Phrenic nerve is blocked 100% of the time and reduces pulmonary function by 25-30%
- Surface landmarks:
 1. Cricoid cartilage (C6)
 2. Lateral border of the clavicular head of the sternocleidomastoid m.
 3. Anterior and middle scalene muscles (interscalene groove)
 4. External jugular vein (?)
- Technique:
 1. Landmark based (nerve stimulation)
 - a. Needle direction *posterior* and *caudad* (superficial 1-1.5 cm)
 - b. Paresthesia or nerve stimulator technique appropriate (anterior shoulder twitch reliable)
 - c. Diaphragmatic twitch – redirect needle location more posterior
 - d. Trapezius twitch – redirect needle more anterior

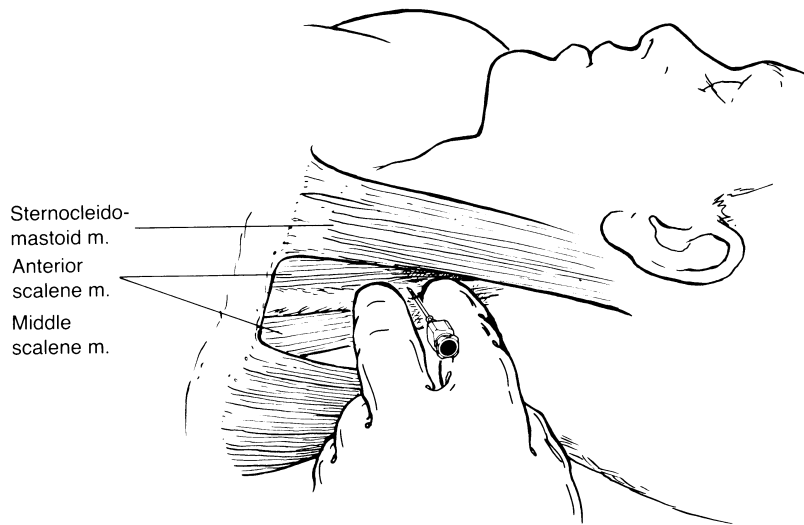


Figure 3. Landmark-based interscalene blockade - fingers palpate the interscalene groove and the needle is inserted with a caudad and slightly posterior angle.

2. Ultrasound guided
 - a. Scanning technique: Start with probe position in supraclavicular fossa, parallel with and contacting clavicle. Identify supraclavicular brachial plexus view and slide probe cephalad, keeping same tilt and angulation of probe.
 - b. Ideal image: Identify the middle scalene and anterior scalene muscles framing the plexus. The scalene muscles may appear as the wings of a butterfly with the plexus as the butterfly's body. Posterior border of sternocleidomastoid m. overlies plexus in ~ 50% of patients.
 - c. Needle approach: In-plane or out-of-plane needle approach may be used.
 - d. Clinical pearls:
 - i. Phrenic nerve resides on superficial aspect of the anterior scalene muscle. It *may* be possible to anesthetize the plexus and not the phrenic nerve if local anesthetic is deposited on posterior aspect of plexus.

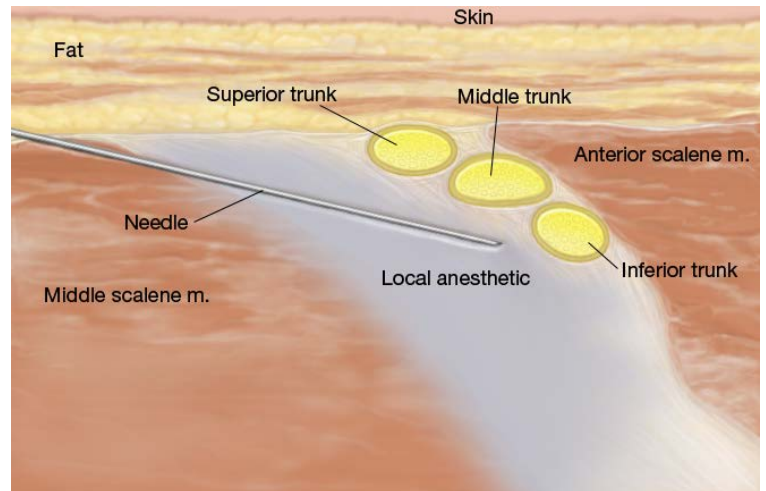
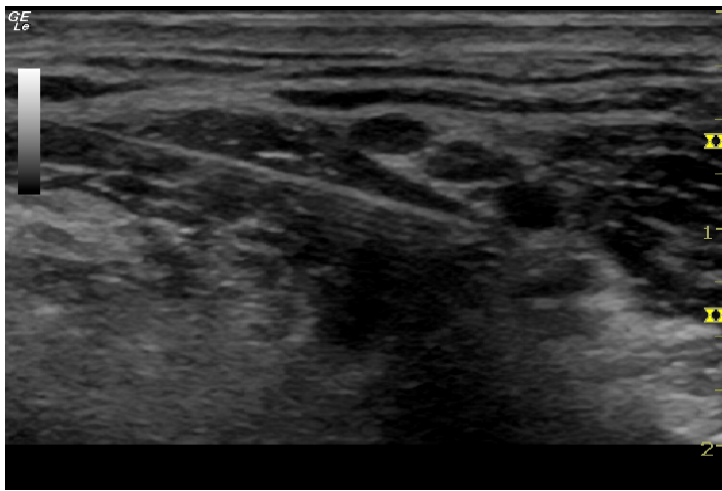
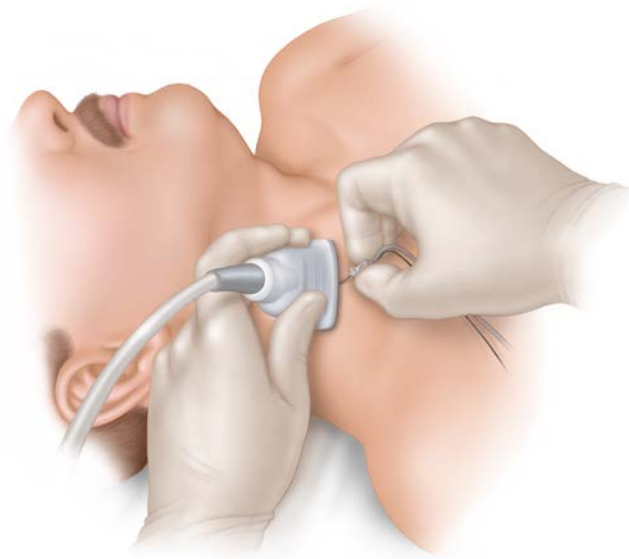


Figure 4. *Ultrasound-guided interscalene blockade* – needle advanced in-plane to posterior aspect of plexus

- Complications: Subarachnoid injection, epidural blockade, intravascular injection, phrenic nerve block, hematoma, local nerve injury, pneumothorax

B. SUPRACLAVICULAR BLOCKADE

- Indication: Surgery of the hand or arm (most consistent & time efficient block)
- Level of blockade: Proximal divisions or trunks
- Limitations:
 1. Significant risk of pneumo-, chylo-, or hemo-thorax
 2. Technically difficult block to master
 3. Obese patients (supraclavicular fat pads)
 4. Caution in outpatients secondary to pneumothorax risk
- Surface landmarks:
 1. Superior border of the clavicle
 2. Clavicular head of the SCM muscle
 3. Subclavian pulse just lateral (2.5 cm) to the clavicular head of the SCM
- Technique:
 1. Landmark based (nerve stimulation)
 - a. Classic:
 - i. Needle insertion 2.5cm lateral to clavicular head of SCM, above the 1st rib, and 1cm above the superior border of the clavicle (near mid-point of the clavicle, immediately lateral to the subclavian pulse)
 - ii. Needle direction: caudad, slightly posterior (depth: 2-3cm)

- iii. Encounter 1st rib: walk anterior-posterior along the rib
 - iv. Encounter subclavian artery: redirect more posterolaterally
- b. Plumb-bob:
- i. Needle inserted at intersection of lateral border of SCM with the clavicle at a 90° angle to the table
 - ii. Needle direction: posterior; walked within the parasagittal plane cephalad (30°) if no paresthesia or twitch is elicited

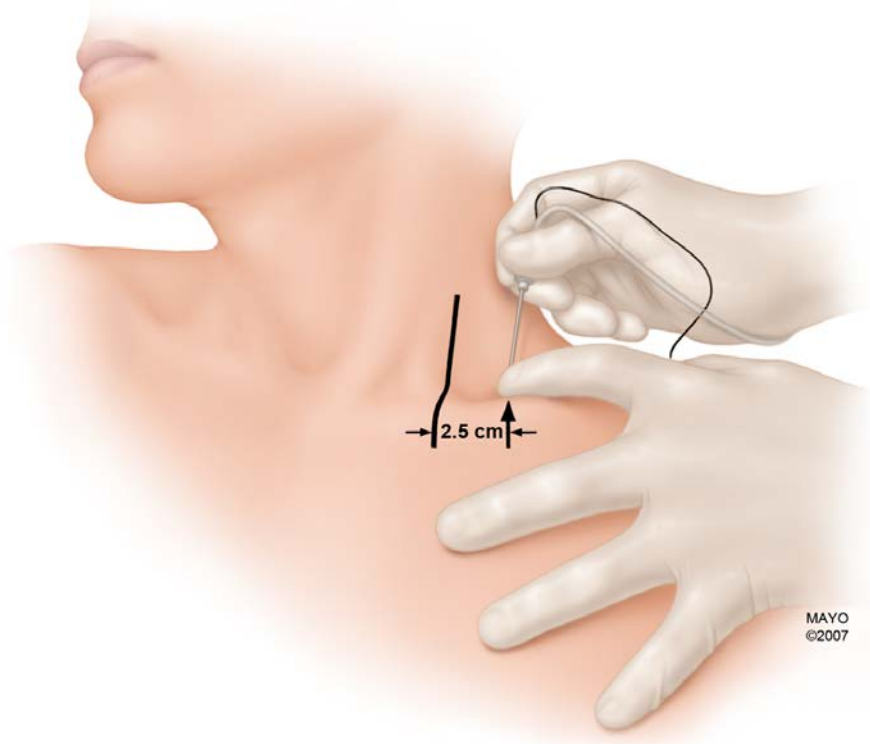


Figure 5. Landmark-based supraclavicular blockade - classic approach

2. Ultrasound guided
- a. Scanning technique: Start with the probe position within the supraclavicular fossa, parallel with and contacting the clavicle.
 - b. Ideal image: Identify subclavian artery, first rib, lung, and divisions of the brachial plexus. Use color Doppler (if necessary) to delineate vascular structures. Adjust the image depth to view as much of the first rib as possible.
 - c. Needle approach: In-plane approach for maximum needle visualization.
 - d. Clinical Pearls:
 - i. Place a folded blanket between the shoulder blades and rotate the patient's head away from the side to be blocked. This opens up the supraclavicular fossa for optimal scanning and maneuvering.
 - ii. Visualize needle and first rib throughout the block. Losing track of either one may result in a pneumothorax.
 - iii. Inject deepest, farthest structures first for safety and to improve visualization.
 - iv. C8-T1 distribution sparing (ulnar n.) may occur if local anesthetic is not placed at the junction between the first rib and the subclavian artery (i.e. 'the corner pocket')

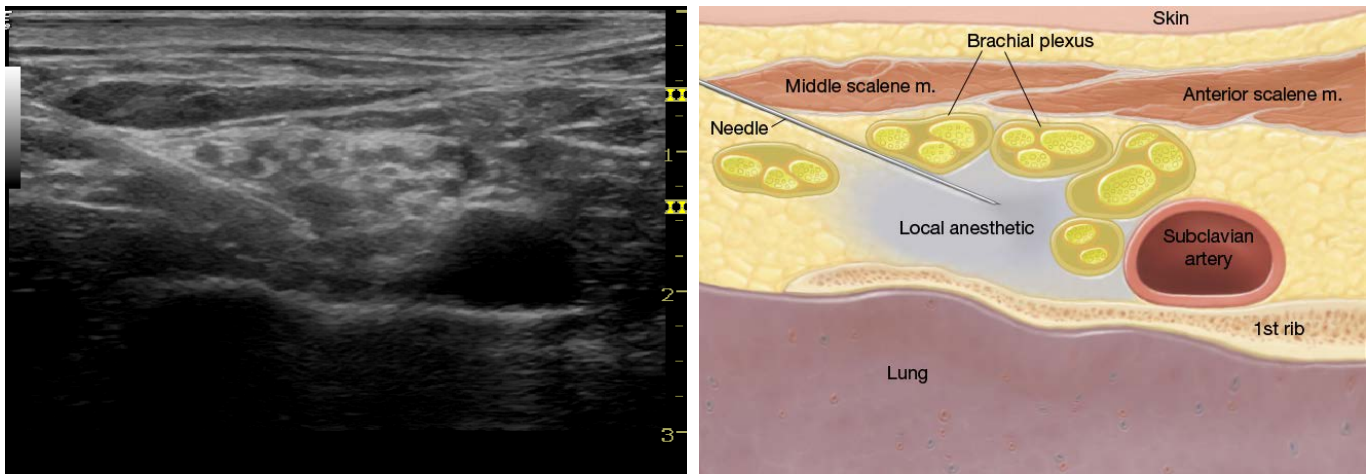
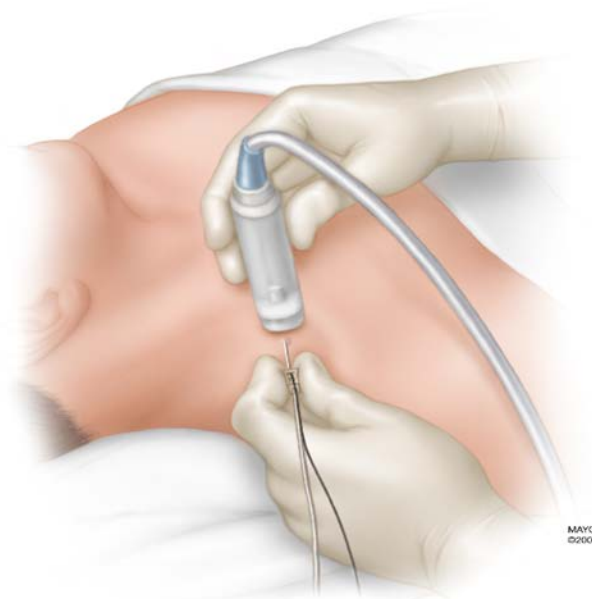


Figure 6. *Ultrasound-guided supraclavicular blockade – needle advanced in-plane to deep aspect of plexus*

- Complications: Pneumothorax (0.5-6%), phrenic nerve blockade (50%), subclavian artery puncture, hematoma, intravascular injection, local nerve injury. *Needle should NOT pass below the clavicle.*

C. INFRACLAVICULAR BLOCKADE

- Indication: Surgery of the hand and arm (elbow or forearm)
- Level of blockade: Distal cords to proximal branches
- Limitations:
 1. Prolonged latency (?)
 2. Discomfort during block placement
- Surface landmarks:
 1. Head of the humerus
 2. Midpoint of the clavicle
 3. Acromioclavicular joint
 4. Coracoid process - identified by palpating deep and medial to the head of the humerus and acromioclavicular joint just inferior to the clavicle
- Technique:
 1. Landmark based (nerve stimulation)
 - a. Needle insertion 2 cm medial and 2 cm inferior to the tip of the coracoid process
 - b. Needle advanced directly posterior in a vertical paramedian plane
 - c. Depth is dependent upon body habitus, ranging from 2.5 to 3 cm in slender patients and 6 to 8 cm in more obese patients

- d. If no paresthesia or twitch elicited (expected depth 2.5-7cm), redirect in cephalocaudad arc
- e. Needle should *not* be directed laterally or medially from the plane of insertion
 - i. Medial redirection may increase the risk of pneumothorax
 - ii. Lateral redirection may place the needle tip lateral to the cords resulting in incomplete anesthesia from insufficient local anesthetic spread

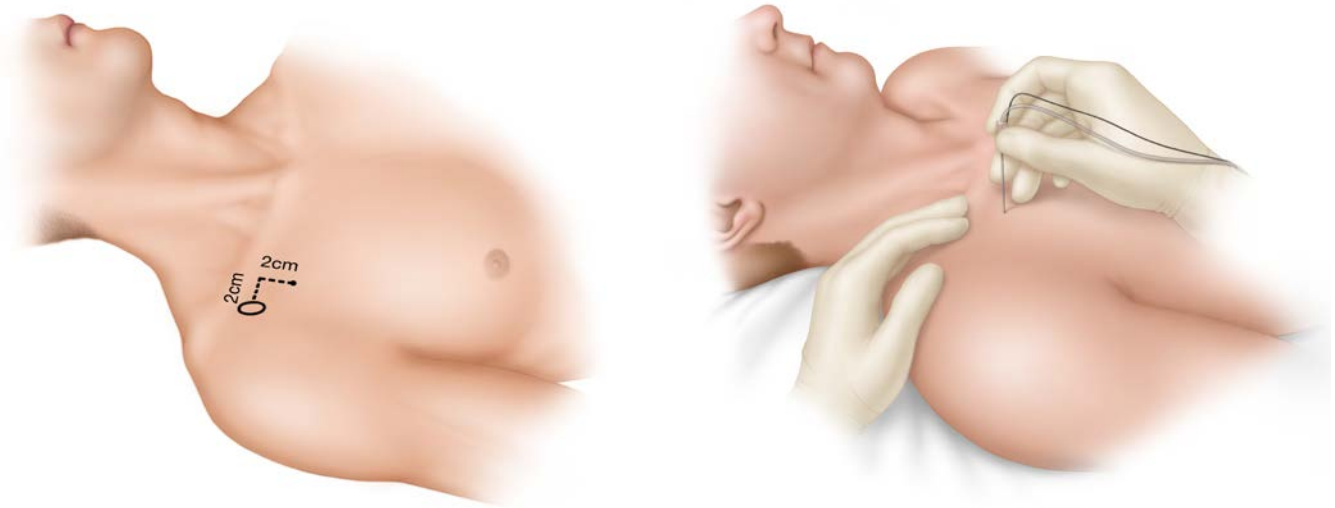


Figure 7. Landmark-based infraclavicular blockade - coracoid approach

- 2. Ultrasound guided
 - a. Scanning technique: Start with the probe in parasagittal orientation immediately caudad to the clavicle and laterally against the humerus
 - b. Ideal image: Identify the pectoralis major and pectoralis minor muscles, the axillary (subclavian) artery and vein, and the cords of the brachial plexus. Use color Doppler to delineate vascular structures.
 - c. Needle approach: In-plane or out-of-plane approach may be used
 - d. Clinical pearls:
 - i. Suboptimal needle visualization when compared to other approaches to the brachial plexus (greater depth of the brachial plexus, steeper needle trajectory).
 - ii. Adduction and external rotation of upper extremity may bring the brachial plexus to a more superficial location
 - iii. Smaller footprint probes may allow more space directly beneath the clavicle to work. However, it will also provide a narrower (i.e. smaller) field of view.

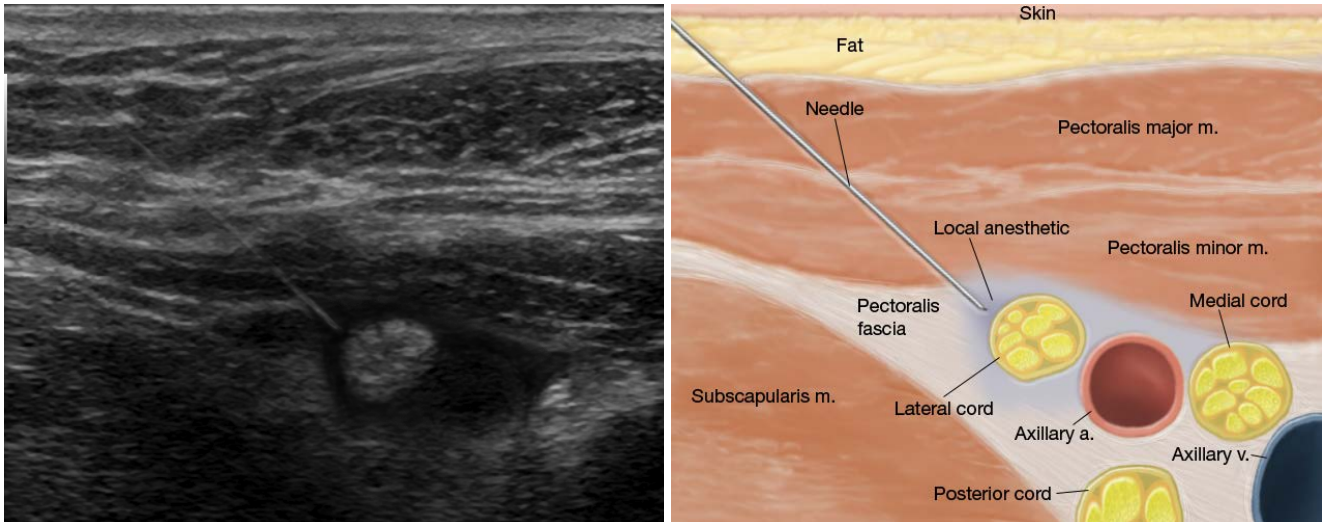
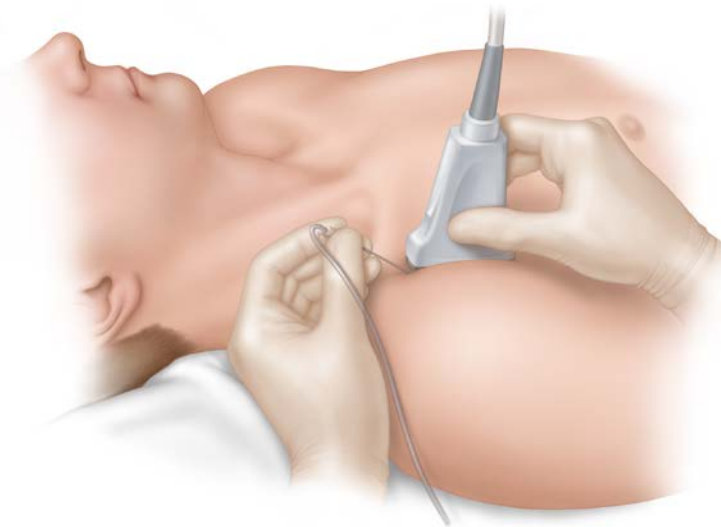


Figure 8. *Ultrasound-guided infraclavicular blockade* – needle advanced in-plane adjacent to lateral cord

- Complications: Brachial or axillary artery or vein puncture, hematoma, local nerve injury, pneumothorax (if too medial)

D. AXILLARY BLOCKADE

- Indication: Surgery of the hand and arm (elbow or forearm)
- Level of blockade: Terminal branches
- Limitations:
 1. Spraying of musculocutaneous and axillary nerves
 2. Poor technique for proximal (above the elbow) procedures
 3. Optimal success rates may require “multiple injections”
- Surface landmark: Axillary artery pulse (below coracobrachialis & lateral to pec. major)
- Patient position: Supine with arm abducted 90° to the body and elbow flexed to 90°
- Technique:
 1. Landmark based
 - a. Transarterial: Needle is directed toward the axillary pulse. Local anesthetic is injected immediately behind and/or in front of the artery.
 - b. Paresthesia: Needle is directed above or below the pulse to locate the median (superior), ulnar (inferior), or radial (posterior) nerves.

- c. **Nerve Stimulator:** Insulated needle is advanced towards the sheath until a motor response is elicited at 0.5mA or less. Motor responses at higher currents may *reduce* success rates. Multiple injections may *improve* success rates.
- d. **Perivascular:** Blunt needle is advanced near the artery until a “pop” is detected. Decrease needle angle to the skin and advance 1cm further. Needle movement produced by transmitted arterial pulsations confirms position in the sheath.

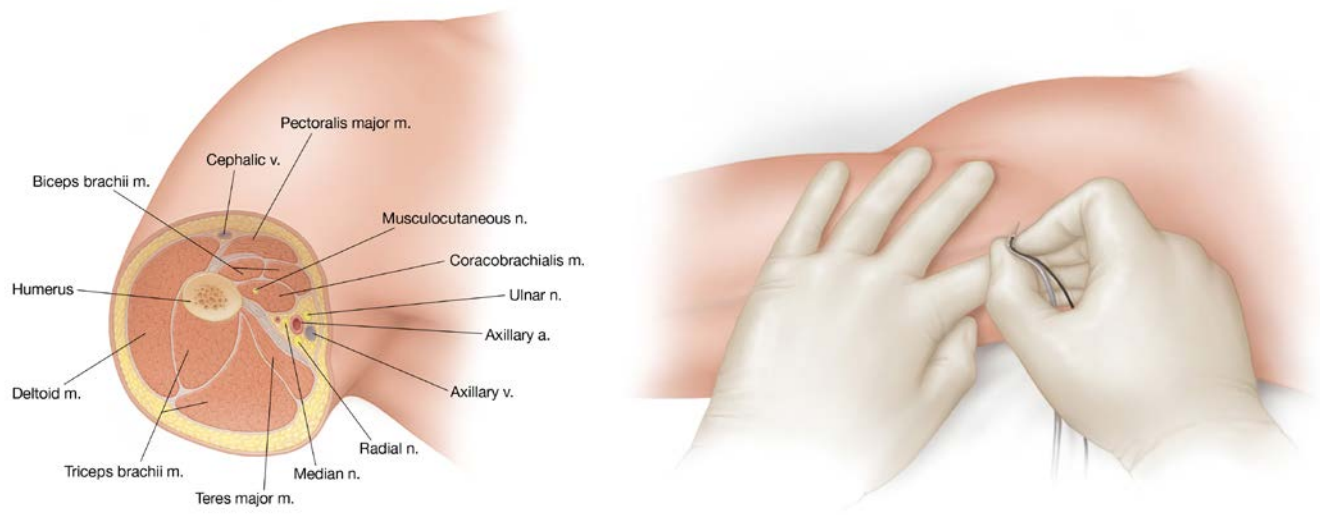

Figure 9. Landmark-based axillary blockade

2. Ultrasound guided

- a. **Scanning technique:** Start with the arm adducted, flexed at the elbow, and externally rotated (traditional axillary block position). Orient probe for a cross-sectional view of neurovascular structures.
- b. **Ideal image:** Identify humerus, axillary artery and vein, musculocutaneous, median, ulnar, and radial nerves, and biceps, coracobrachialis, and triceps muscles.
- c. **Needle approach:** In-plane or out-of-plane needle approaches may be used.
- d. **Clinic pearls:**
 - i. Greatest variation of neuroanatomic positions.
 - ii. Nerve stimulation in conjunction with ultrasound is useful for determining nerve identity.
 - iii. Often difficult to bring all three nerves (median, ulnar, radial) into view at the same time (radial nerve is often out of plane).
 1. Scan first to identify the best view of the deepest/farthest structures.
 2. Deposit local anesthetic, then modify scan by subtle probe position movements to bring shallower/closer structures into view before depositing additional local anesthetic
 3. Musculocutaneous nerve is best viewed several centimeters distal to the axillary crease, and by scanning more cephalad/superior onto the biceps (often a separate more cephalad needle puncture is required for optimal needle-beam orientation and best needle visualization)

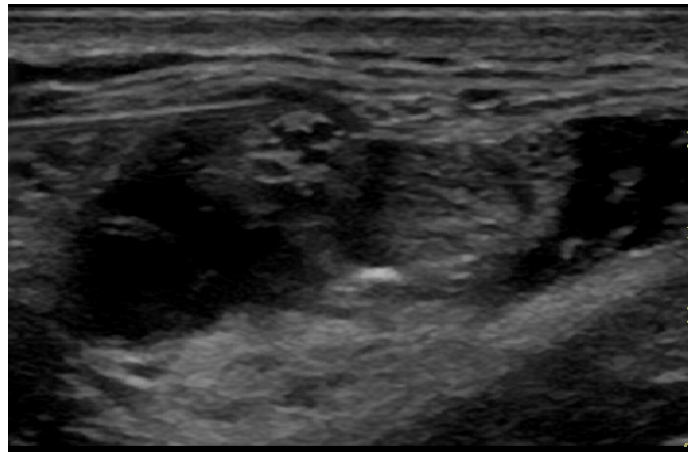
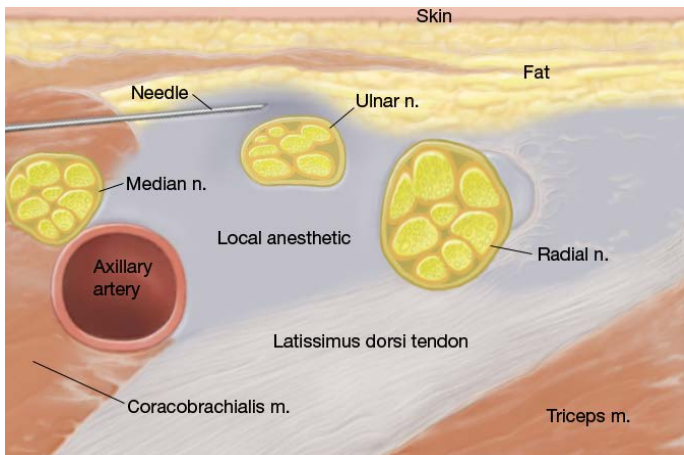
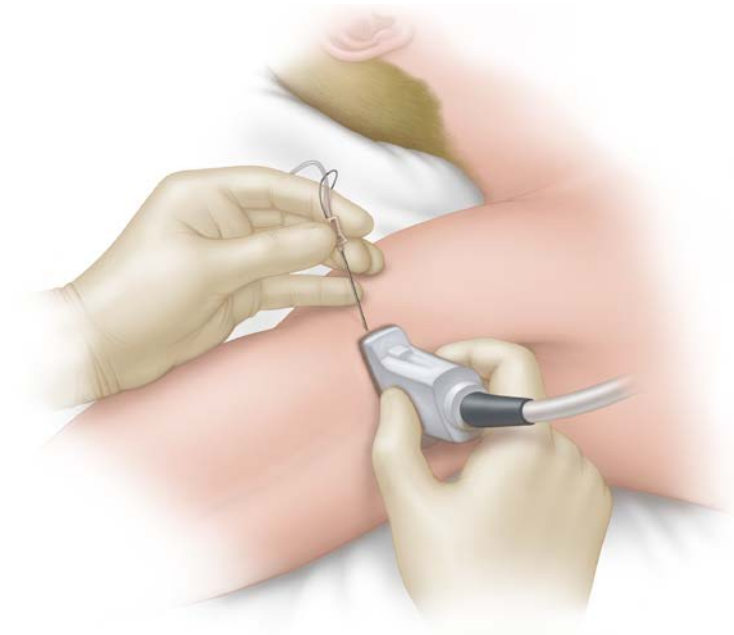


Figure 10. *Ultrasound-guided axillary blockade* – needle advanced in-plane adjacent to ulnar nerve

- Complications: Local nerve injury (neuropathy), intravascular injection (systemic toxicity), hematoma formation, axillary artery pseudoaneurysm or dissection

III. Lower Extremity Neuroanatomy

A. LUMBAR PLEXUS

- Formed from ventral rami of L1-L3; variable contributions from T12 & L4
- Neural structures located anterior to the transverse processes of the lumbar vertebrae deep within the psoas muscle
- Two major components
 1. Cephalad Component (T12-L1): Superior and Inferior Branches
 - **Superior Branch:** *Iliohypogastric* and *Ilioinguinal* nerves
 - **Inferior Branch:** *Genitofemoral* nerve
 2. Caudal Component (L2-L4):
 - **Lateral femoral cutaneous nerve:** Passes under the lateral end of the inguinal ligament. Provides cutaneous innervation to the lateral portion of the buttock distal to the greater trochanter and to the proximal 2/3 of the lateral aspect of the thigh.
 - **Obturator nerve:** Travels along posteromedial aspect of psoas muscle. Supplies the adductor muscles of the hip and knee, and the medial aspect of the thigh proximal to the knee.
 - **Femoral nerve:** Travels along the lateral border of the psoas muscle, into the groove between the psoas and iliacus, and under the inguinal ligament where it divides into several branches that supply the anterior thigh, hip, and knee joints. Terminal branch includes the *saphenous nerve*, which innervates the medial aspect of the lower leg, ankle, and foot.

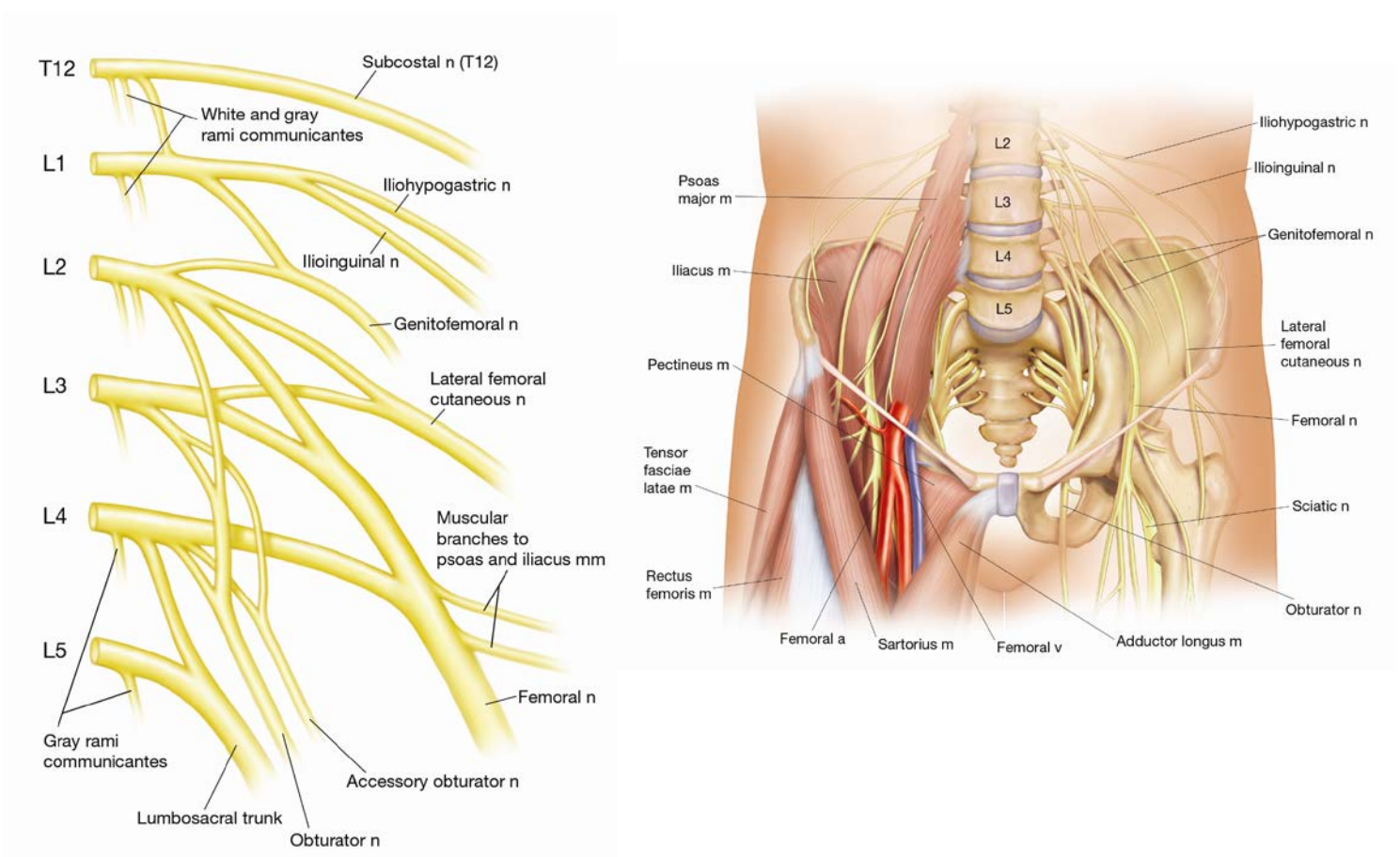


Figure 11. Lumbar plexus

B. LUMBOSACRAL PLEXUS

- Formed from the ventral rami of L4-S3, variable contribution from S4
- Neural structures located on the anterior surface of the lateral sacrum, anterior to the piriformis muscle. Exit the pelvis posteriorly via the sciatic notch, and course anterior to the gluteus maximus muscle.
- **Sciatic Nerve:** Formed from the fusion of two major nerve trunks
 1. **Tibial nerve (medial trunk):** Derived from anterior branches of L4-S3. Course posteromedial to the femur, and separate from the peroneal nerve at the cephalad portion of the popliteal fossa (occasionally higher than this). Passes between the heads of the gastrocnemius muscles and divides into several terminal branches.
 - **Posterior tibial nerve** (Heel and planter aspect of foot)
 - **Sural nerve** (Lateral aspect of foot)
 2. **Peroneal nerve (lateral trunk):** Derived from the posterior branches of L4-S3. Upon separation from tibial nerve, courses along the cephalolateral margin of the popliteal fossa. Supplies cutaneous innervation to the posterolateral aspect of the lower leg. Travels around the head of the fibula, and divides into two terminal nerves.
 - **Deep peroneal nerve** (Web-space of Great toe)
 - **Superficial peroneal nerve** (Dorsal aspect of foot)
- **Posterior Femoral Cutaneous Nerve:** Branches off the sciatic nerve prior to exiting the pelvis, courses with the sciatic nerve, and provides cutaneous innervation to the posterior aspect of the upper leg.

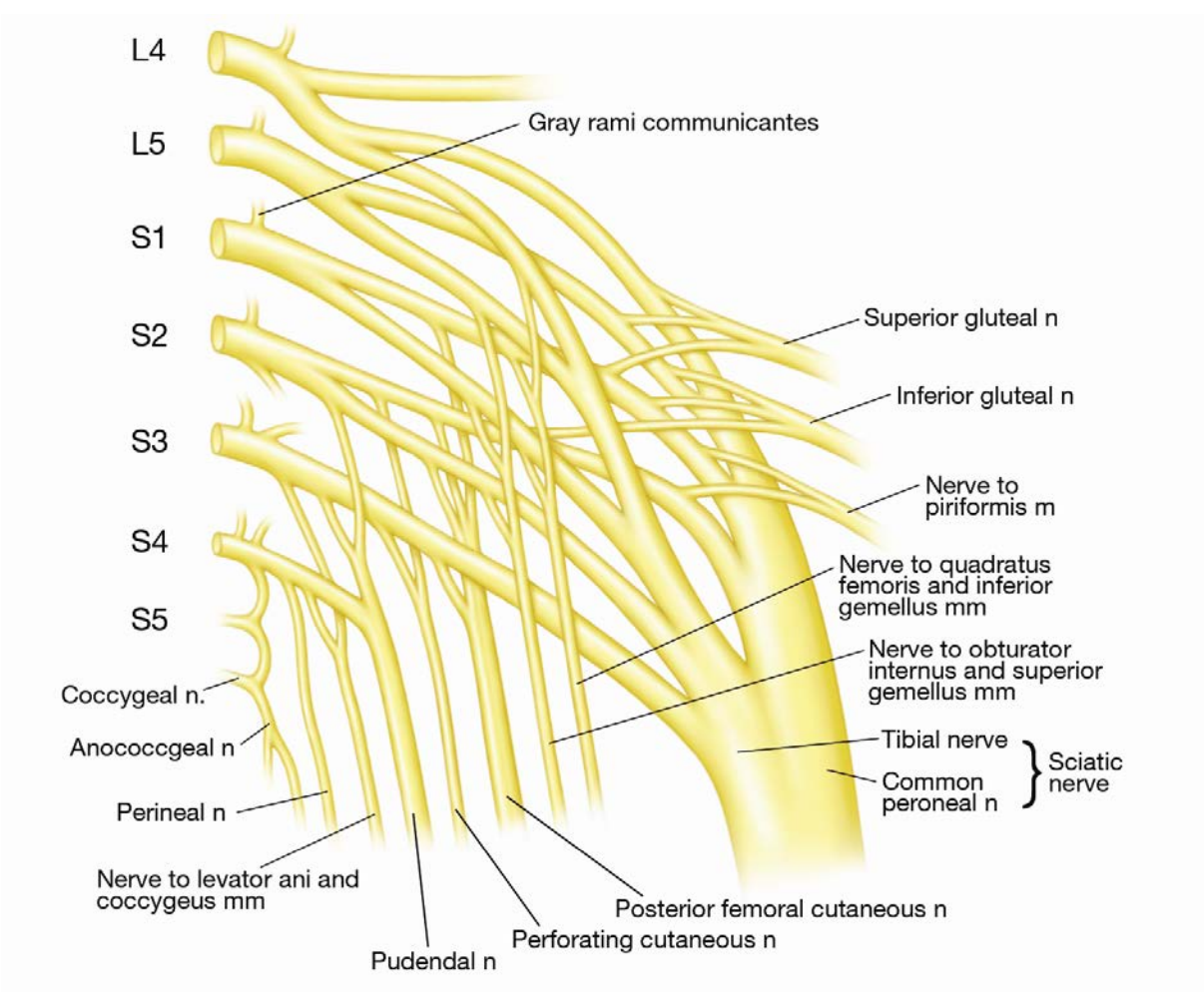


Figure 13. Lumbosacral plexus

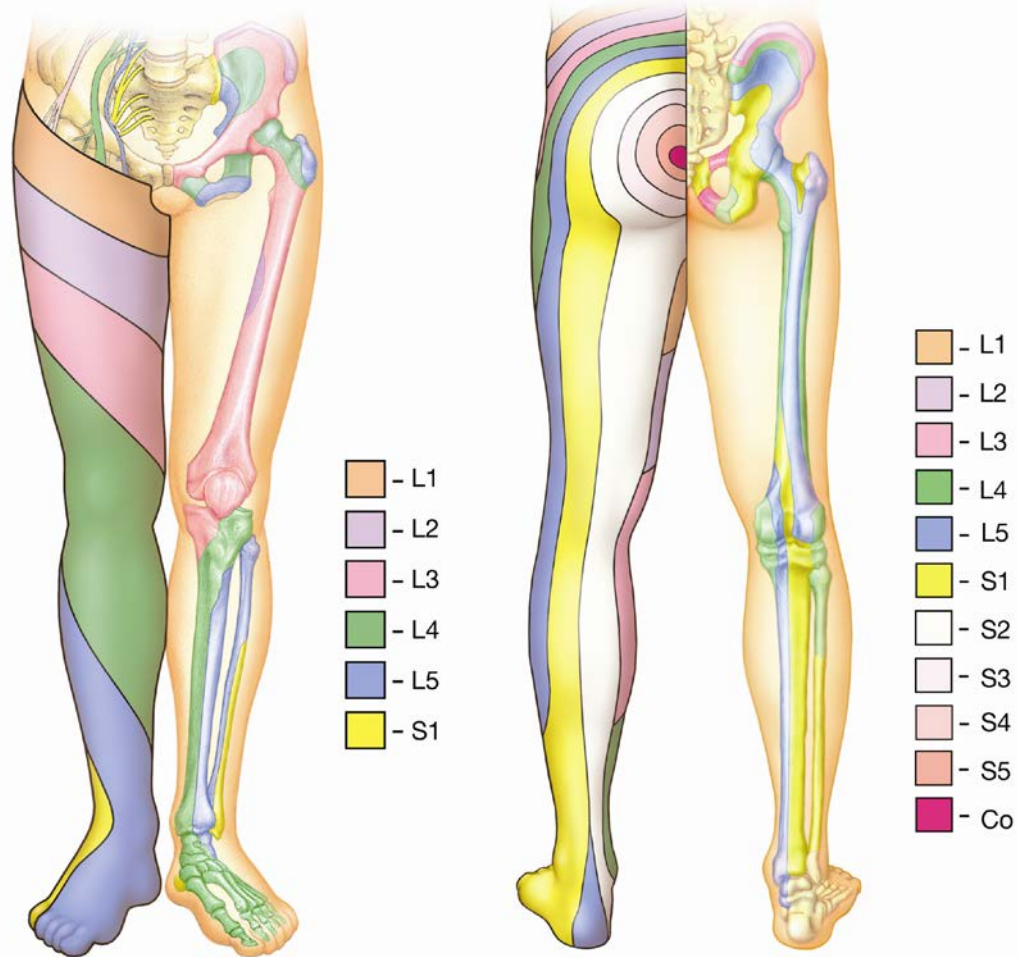
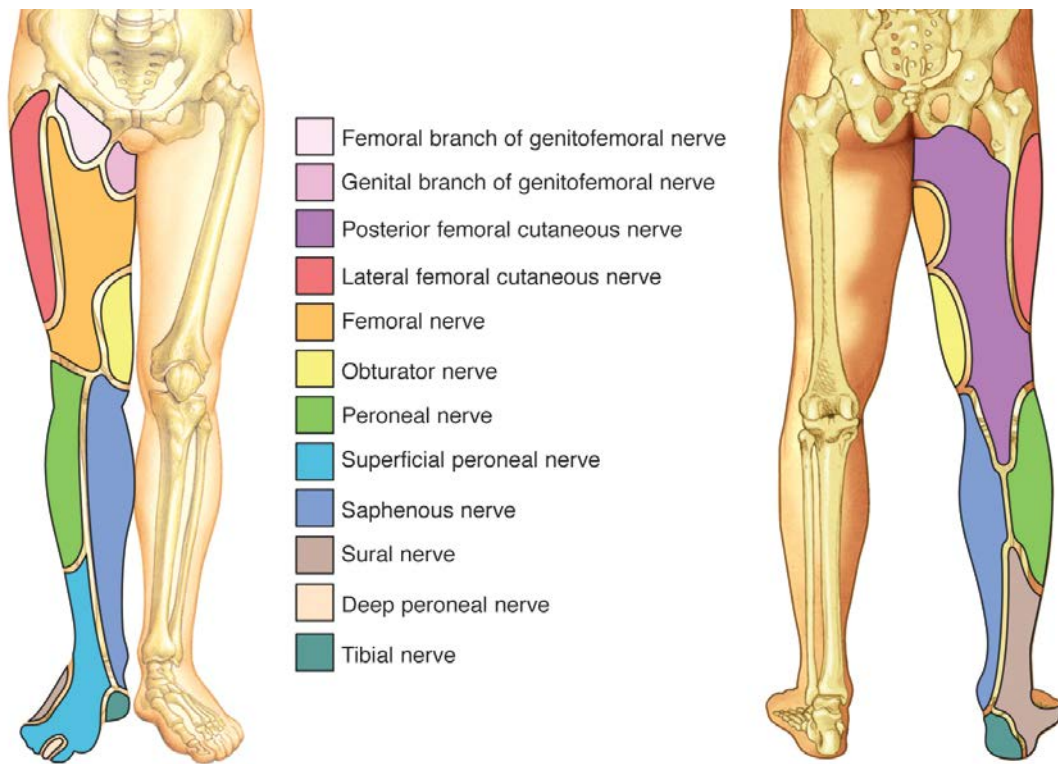


Figure 14 Lower extremity innervation (dermatomes, osteotomes)

IV. Lower Extremity Regional Techniques

A. PSOAS COMPARTMENT

- Indication: Surgery of the anterolateral or anteromedial thigh, hip, knee, or medial leg
- Level of Blockade: Lumbar plexus (T12-L4) within the psoas compartment at ~ L4 - L5
- Limitations:
 1. Rarely adequate as the sole anesthetic for lower limb surgery (i.e. often requires supplemental blockade of the lumbosacral plexus)
 2. Considered a technically difficult block to master
 3. Sciatic and/or epidural spread in 4% - 10.7% of cases
 4. Poorly visible, non-compressible site (unrecognized bleeding)
- Surface landmarks: Iliac crest, vertebral spinous processes (i.e. midline), PSIS
- Technique:
 1. Landmark based (nerve stimulator)
 - a. Lateral decubitus position (operative-side up) with hips and knees flexed (i.e. fetal position)
 - b. Needle inserted 5 cm lateral and 3 cm caudad to L4 spinous process (*OR* 1 cm cephalad from the intersection of the two lines extending from the iliac crest and posterior superior iliac spine)
 - c. Needle direction perpendicular to the skin in all planes
 - d. Contact bone (= transverse process of L4 or L5) after 4-6 cm → walk caudad off transverse process 1-2 cm deeper until elicitation of quadriceps motor response (current ≤ 0.5 mA)

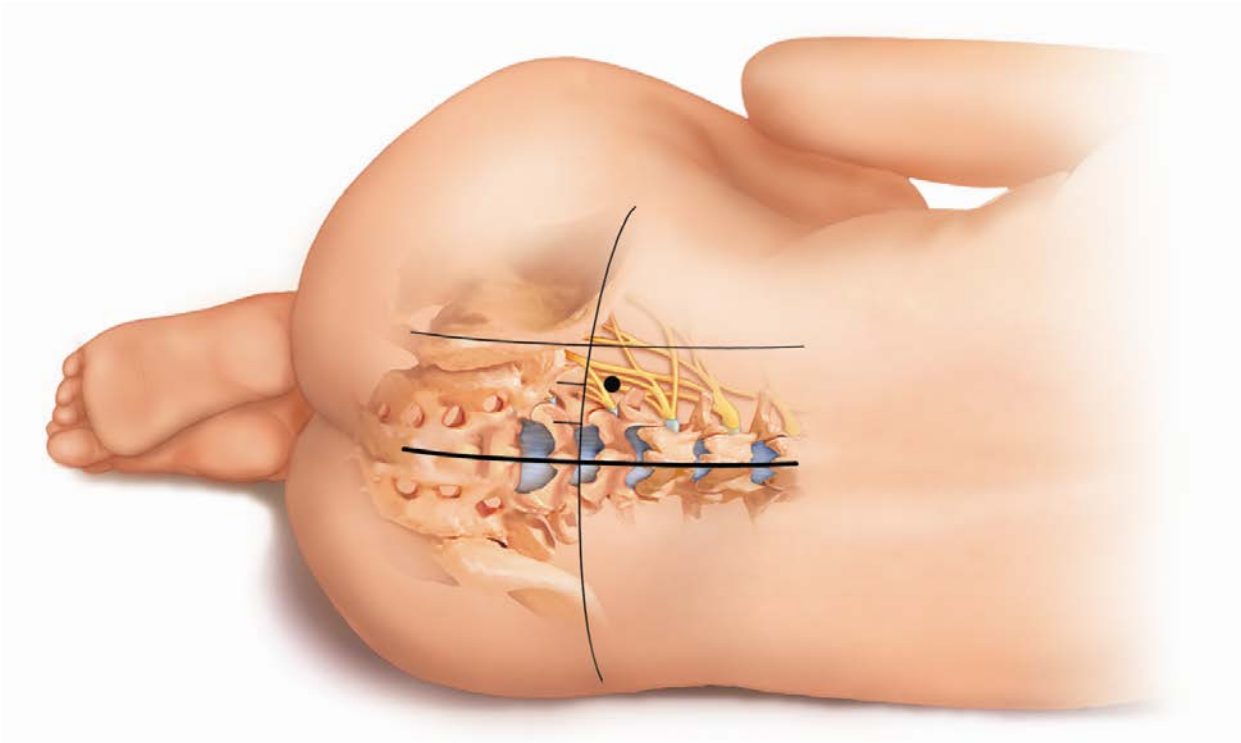


Figure 15. Landmark based psoas compartment blockade (patient position, surface landmarks)

- Complications: Subarachnoid injection; epidural blockade; intravascular injection (systemic toxicity); hematoma formation; local nerve injury (neuropathy); infection/abscess

B. FEMORAL NERVE BLOCK

- Indication: Surgery of the anterolateral or anteromedial thigh, knee, or medial leg
- Level of Blockade: Terminal branches of lumbar plexus (L2-L4) distal to inguinal ligament
- Limitations:
 1. Rarely adequate as the sole anesthetic for lower limb surgery (i.e. often requires supplemental blockade of the lumbosacral plexus)
 2. Difficult to acquire complete “3-in-1” block
 3. Estimated success rates: femoral (81-100%), lateral femoral cutaneous (62-96%), saphenous (75-100%), and obturator (0-44%)
- Surface landmarks: Inguinal skin crease, femoral artery pulse
- Technique:
 1. Landmark based (nerve stimulation)
 - a. Supine position, the femoral pulse is identified at the inguinal skin crease
 - b. Needle insertion 1 cm immediately lateral to the femoral pulse at or slightly distal to the inguinal crease
 - c. Needle direction at an angle of 30° to the skin with a cephalad direction, inserted to a depth of approximately 2-3 cm
 - d. Elicit quadriceps response with patellar ascension (i.e. patellar snap) at current ≤ 0.5 mA

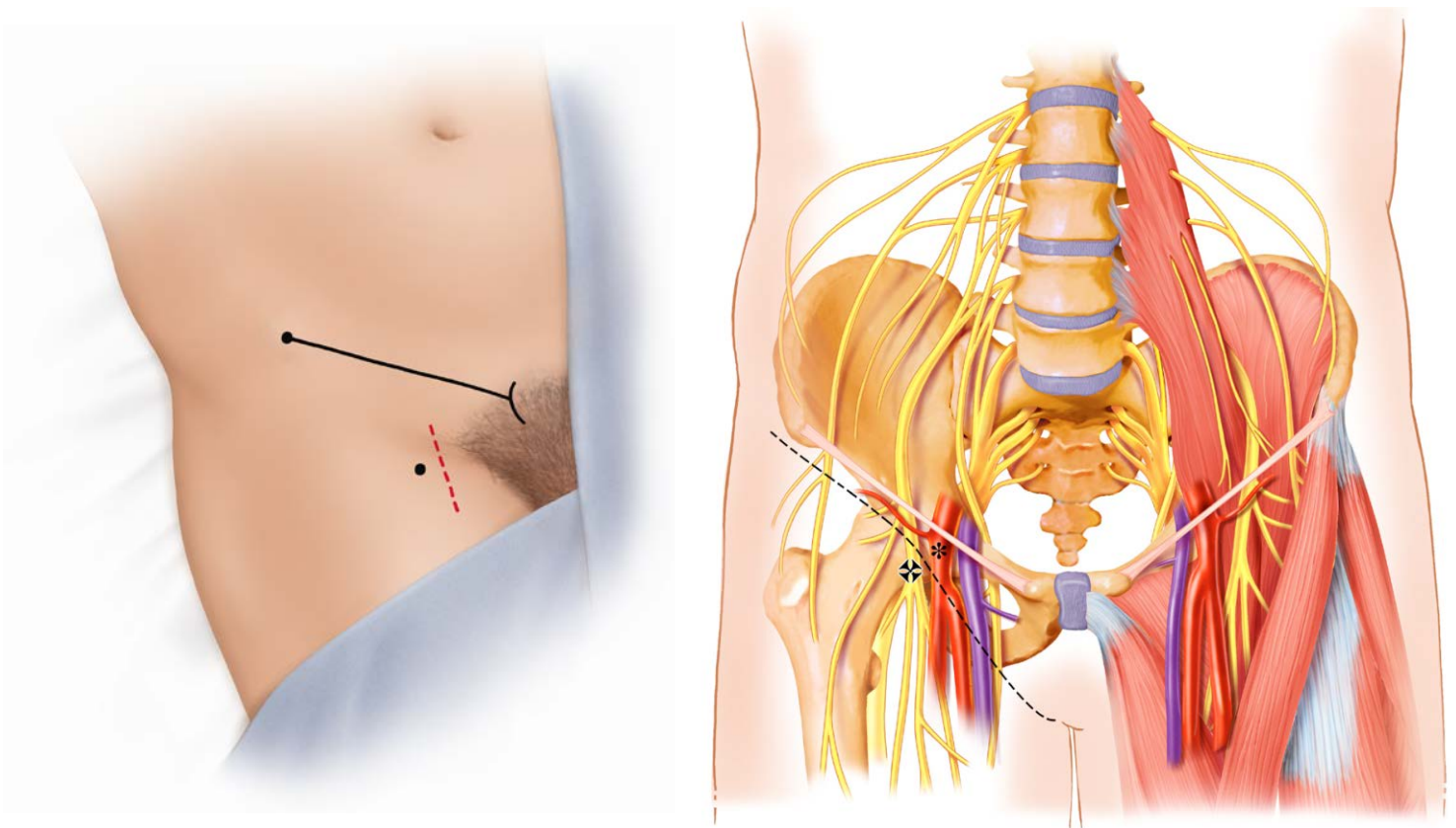


Figure 16. Landmark based femoral nerve blockade

2. Ultrasound guided
 - a. Scanning technique: Start with the probe oriented for cross-sectional (short axis) visualization of the femoral artery at the level of the inguinal crease
 - b. Ideal image: Identify the femoral nerve and artery (*confirm that the scanning plane is above the branch point for the profunda femoris artery*). The nerve will appear as a broad triangular structure between the fascia iliaca and iliacus muscle located lateral to the femoral artery.
 - c. Needle approach: In-plane or out-of-plane needle approach may be used
 - d. Clinical pearls:

- i. Ultrasound is useful for femoral nerve blockade in patients with a large body habitus where anatomic landmarks (i.e. the femoral artery) are difficult to palpate.
- ii. Catheter should advance easily. However, the actual location of the catheter tip will not be easily viewed with ultrasound. Consider air injection or agitated local anesthetic injection to infer catheter tip position.
- iii. Injection of 5% dextrose solution or local anesthetic *via* the needle will confirm spread below the fascia and document the correct tissue plane for catheter placement.

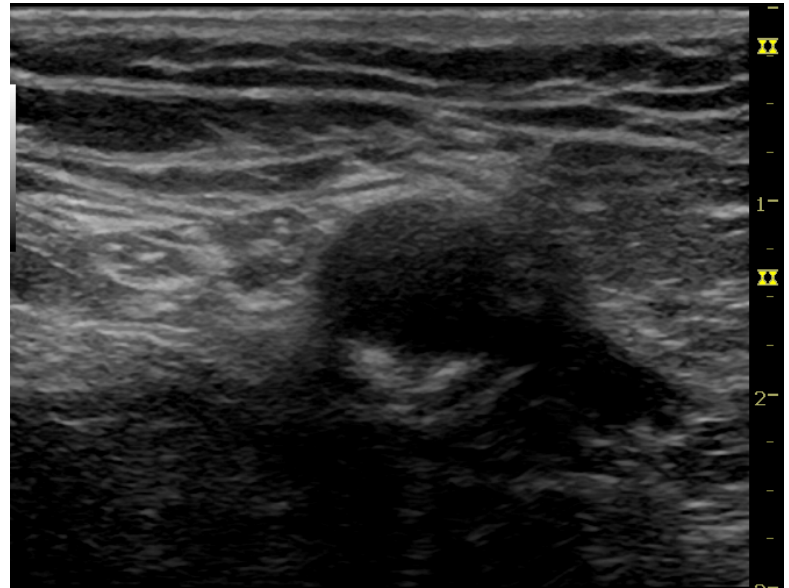
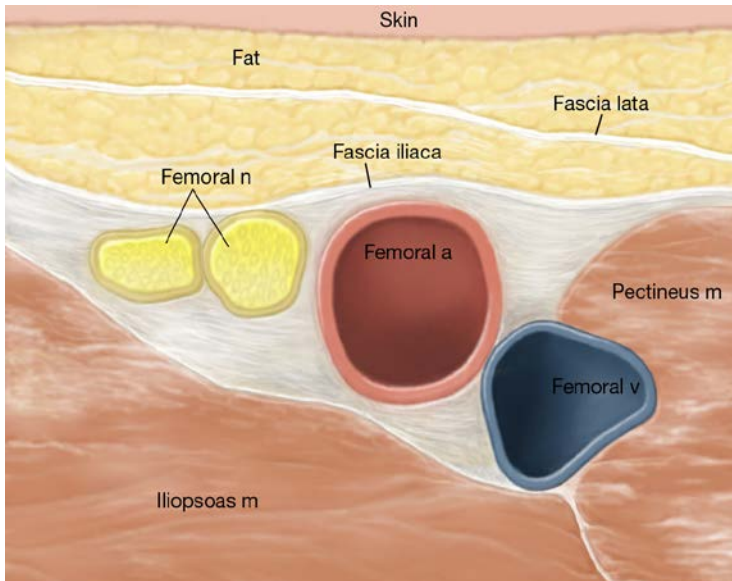


Figure 17. *Ultrasound guided femoral nerve blockade*

- Complications: Local nerve injury, intravascular injection (systemic toxicity), hematoma formation; infection (i.e. vascular grafts)

C. FASCIA ILIACA BLOCK

- Indication: Surgery of the anterolateral or anteromedial thigh, hip, knee, or medial leg
- Level of Blockade: Terminal branches of the lumbar plexus (L2-L4) at the inguinal ligament
- Limitations:
 1. Rarely adequate as the sole anesthetic for lower limb surgery
 2. Difficult to acquire complete “3-in-1” block
 3. Estimated success rates: femoral (88%), LFC (90%), and obturator (38%)
 4. Unpredictable catheter placement during continuous techniques
 5. Requires large volumes of local anesthetic for optimal blockade
- Surface landmarks:
 1. Anterior superior iliac spine
 2. Pubic tubercle
 3. Femoral artery pulse
- Technique:
 1. Landmark based
 - a. Supine position, and a line drawn from the ASIS to the pubic tubercle
 - b. Line representing the inguinal ligament is divided into thirds
 - c. Needle (blunt tip) insertion 1 cm caudal to the point where the lateral and middle thirds meet— be certain the insertion point is lateral to the femoral pulse
 - d. Needle direction is perpendicular to the skin, with advancement until two distinct “pops” are felt (i.e. passage through the fascia lata and fascia iliaca)

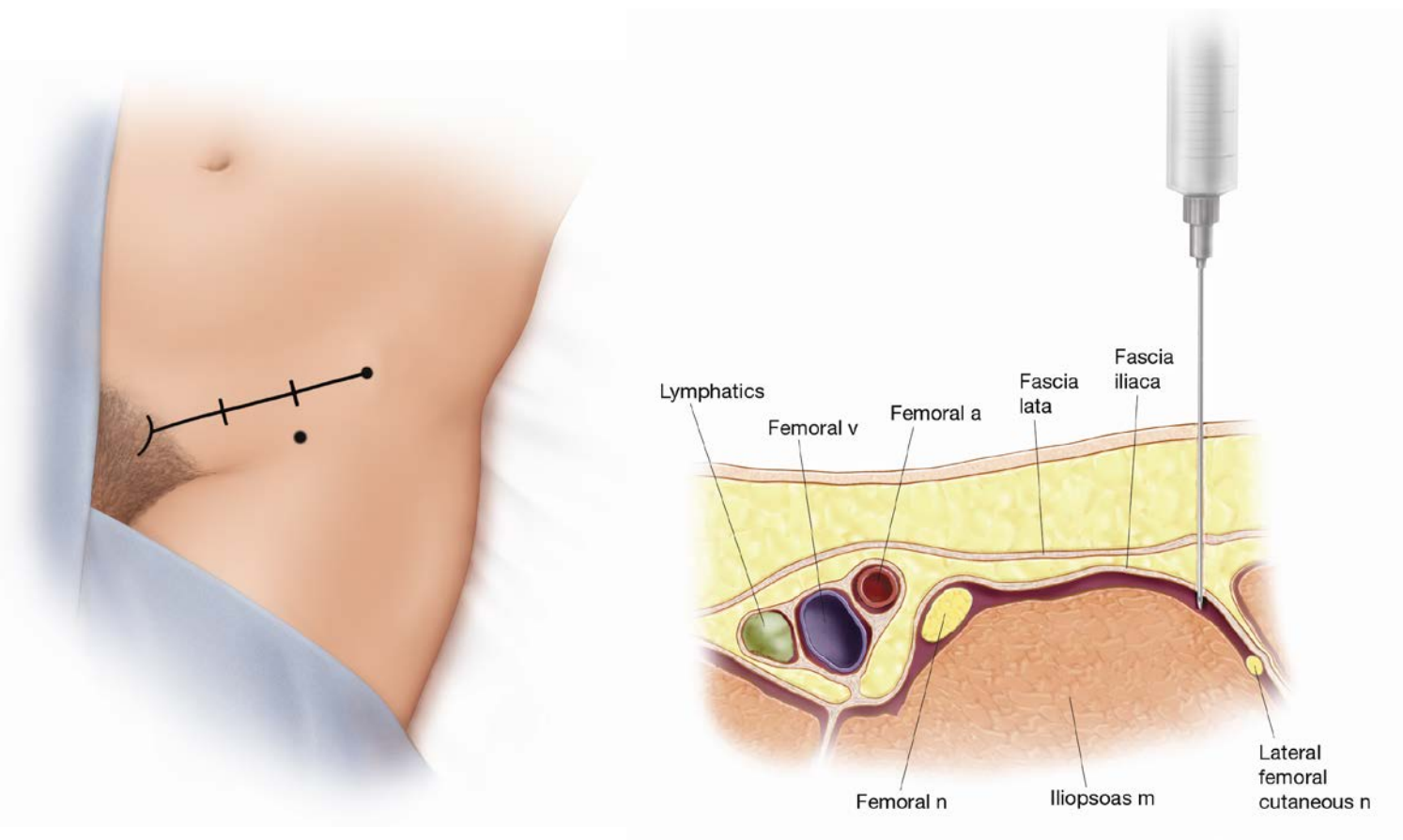


Figure 18. Landmark based fascia iliaca blockade

2. Ultrasound guided
 - a. Scanning technique: Start with the probe oriented for cross-sectional (short axis) visualization of the femoral artery at the level of the inguinal crease. Slide the probe slightly lateral along the inguinal crease so the femoral nerve and vessels appear at the edge of the ultrasound screen.
 - b. Ideal image: The femoral nerve and artery should sit at the edge of the ultrasound image, and the fascia lata and fascia iliaca should appear as 2 distinct hyperechoic layers superficial to the iliopsoas muscle.
 - c. Needle approach: In-plane or out-of-plane needle approach may be used

- Complications: Local nerve injury (neuropathy), intravascular injection (systemic toxicity), hematoma formation, infection

D. SCIATIC NERVE BLOCK

- Indication: Surgery of the knee, distal anterolateral or posterior leg, ankle, or foot
- Level of Blockade: Terminal branch (sciatic nerve, L4-S3) of the lumbosacral plexus
- Limitations:
 1. Rarely adequate as the *sole* anesthetic for lower limb surgery proximal to the ankle (i.e. often requires supplemental blockade of the lumbar plexus)
 2. May require supplementation of the saphenous nerve for distal lower extremity surgery
 3. Positioning for the Classic Labat approach may be difficult in patients with lower extremity trauma
 4. Anterior approach may be difficult in obese patients (poor identification of landmarks)
- Surface landmarks:
 1. Classic (Posterior) Labat Approach
 - a. Posterior superior iliac spine (PSIS)
 - b. Greater trochanter
 - c. Sacral hiatus

2. Subgluteal Approach
 - a. Greater trochanter
 - b. Ischial tuberosity
 3. Anterior Approach
 - a. Anterior superior iliac spine (ASIS)
 - b. Pubic tubercle
 - c. Greater trochanter
- Techniques
 1. Landmark-based
 - a. Classic (Posterior) Labat Approach
 - i. Lateral position (operative side up) with the upper (non-dependent) hip and knee slightly flexed (a.k.a. Sim's Position)
 - ii. Line is drawn connecting the PSIS to the midpoint of the greater trochanter. Perpendicular to this line, a second line is drawn caudomedially for 5 cm. The endpoint of this line (= needle insertion point) should approximate yet another line drawn from the sacral hiatus to the midpoint of the greater trochanter
 - iii. Needle inserted perpendicular to the skin in all planes
 - iv. Search for appropriate motor response (foot plantar- or dorsi-flexion) at a stimulating current of $<0.5\text{mA}$. If bone is contacted, walk needle more medially along the line extending from the sacral hiatus to the greater trochanter
 - b. Subgluteal Approach
 - i. Lateral position (operative side up) with the upper (non-dependent) hip and knee slightly flexed (a.k.a. Sim's Position)
 - ii. Line is drawn connecting the midpoint of the greater trochanter and the ischial tuberosity. Perpendicular to the midpoint of this line, a second line is drawn caudally 4 cm
 - iii. Needle inserted at an angle of 80° with the skin
 - iv. Search for appropriate motor response (as above) at a stimulating current of $<0.5\text{mA}$
 - v. Pearl: Lateral needle redirection may promote a more distal twitch
 - c. Anterior Approach
 - i. Supine position, leg in the neutral position
 - ii. Line is drawn from the ASIS to the pubic tubercle. The line is then trisected. A second line is extended inferomedially from the greater trochanter that is parallel to the first line drawn above. A line is then drawn perpendicular to the first line, extending from the junction of the medial third and lateral two-thirds until it comes into contact with the second line drawn (= needle insertion point).
 - iii. Needle inserted perpendicular to the skin in all planes
 - iv. After contacting bone (femur), redirect the needle medially, and advance approximately 5 cm deeper than the point of contact with bone (sciatic nerve is located posteromedially to the femur)
 - v. Elicit appropriate motor response (foot plantar- or dorsi-flexion) at a current of $<0.5\text{mA}$
 - vi. Pearl: If unsuccessful with the leg in the neutral position, attempt to rotate the leg internally

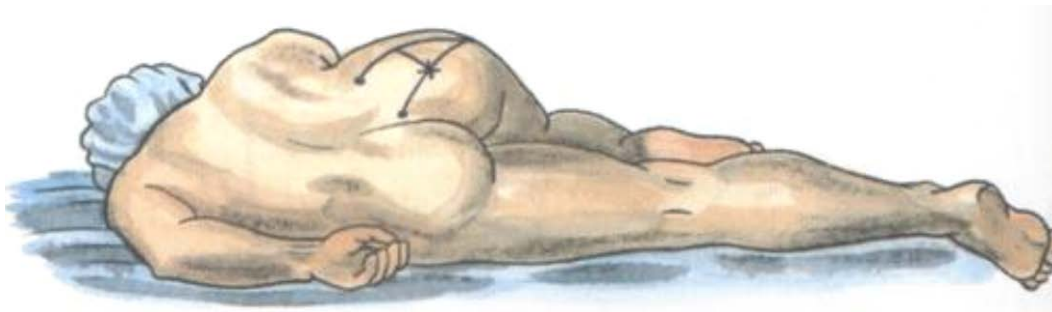

Figure 19. *Sim's position*

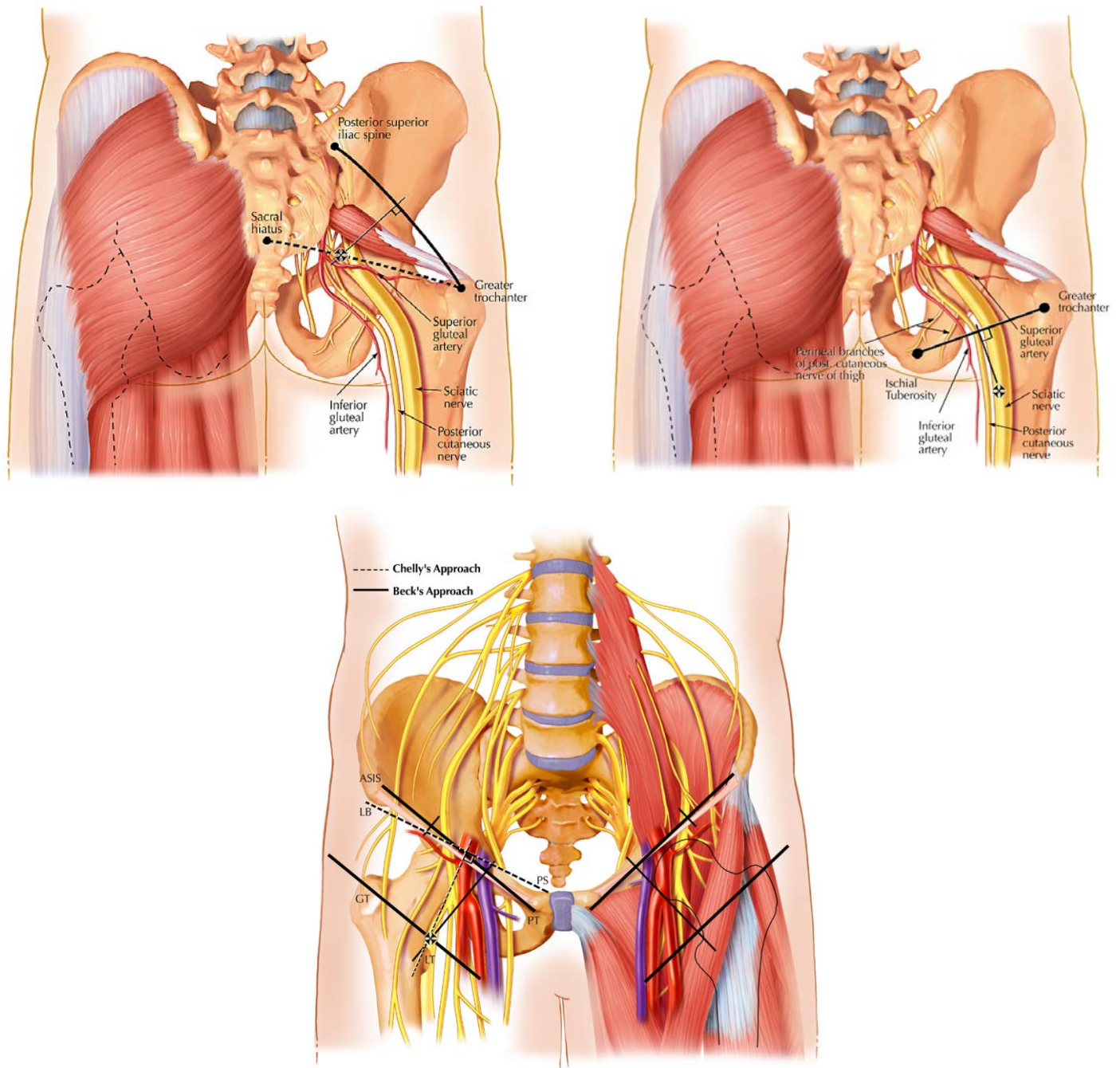


Figure 20. Landmark based sciatic nerve blockade (classic, subgluteal, and anterior approaches)

2. Ultrasound-guided

- a. Scanning technique: Start with the patient in the Sims' position. Place the probe perpendicular to the long axis of the limb on the posterior surface of the proximal thigh immediately distal to the gluteal muscles.
- b. Ideal image: Identify the gluteus maximus, greater trochanter, ischial tuberosity, and sciatic nerve. The nerve will appear as a round or elliptical/linear hyperechoic structure between the greater trochanter and the ischial tuberosity. In some patients, the nerve may appear "flattened" as it is compressed between the layers of the quadratus femoris and gluteus maximus muscles.
- c. Needle approach: In-plane or out-of-plane needle approach may be used
- d. Clinical pearls:
 - i. In patients with a small body habitus, a high-frequency linear probe may produce adequate images. However, most patients will require imaging with a low-frequency curvilinear probe.

- ii. Greater trochanter and the ischial tuberosity are two easily identifiable bony landmarks that create an anatomical frame of reference during sciatic imaging. Locating these structures will facilitate the identification of the sciatic nerve.
- iii. Optimal sonographic visualization may require minor adjustments in probe angulation to distinguish the sciatic nerve from adjacent muscular and fascial structures.
- iv. Elliptical-shaped nerve is commonly surrounded by a dense hyperechoic border, representing the aponeurosis of the surrounding musculature.

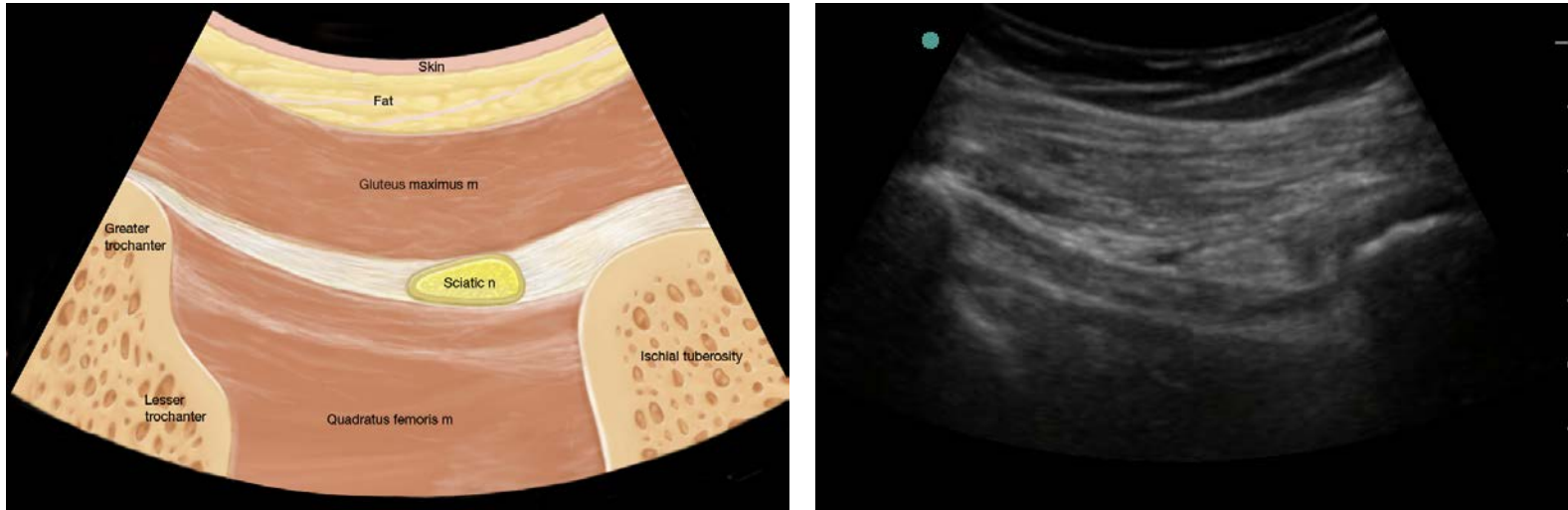


Figure 21. *Ultrasound guided subgluteal sciatic nerve blockade (anatomic illustration and US image)*

- Complications: Local nerve injury; intravascular injection (systemic toxicity); hematoma formation; infection; Postoperative dysesthesias are reportedly higher with sciatic nerve blockade when compared to other peripheral nerve blocks

E. POPLITEAL BLOCK

- Indication: Surgery below the knee (usually combined with saphenous nerve block to obtain complete anesthesia)
- Level of Blockade: Terminal branches of the lumbosacral plexus (peroneal and tibial nerves) at the popliteal fossa.
- Limitations:
 1. Does not provide blockade of surgical fields within the saphenous nerve distribution
 2. Prone positioning (necessary for classic approach) may be difficult in obese patients, trauma patients, or parturients
- Technique:
 1. Landmark-based
 - a. Classic (Posterior) approach
 - i. Prone or Sim's position
 - ii. Needle entry site is 5 cm cephalad along the line perpendicular to the crease and 1 cm lateral
 - iii. Needle is introduced 40-60° antero-superiorly and slowly advanced until a branch of the sciatic nerve is stimulated
 1. Common peroneal nerve stimulation: dorsiflexion of the foot and extension of toes or eversion
 2. Tibial nerve stimulation: plantar flexion of the foot and toes or inversion of the foot'
 - iv. Adjust needle position to achieve a motor response $\leq 0.5\text{mA}$
 - v. Clinical pearls
 1. Anatomic landmarks can be identified by asking the patient to actively flex the leg
 2. If the needle is initially misdirected, it is usually directed too far medially

b. Lateral approach

- i. Supine position with knee slightly flexed
- ii. Needle insertion site is at the intersection of a line drawn from the top of the patella to the groove between the muscles described above.
- iii. Needle inserted with an angle of 30° posterior and 45° cephalad
- iv. Advance needle to achieve a motor response $\leq 0.5\text{mA}$. Common peroneal nerve is generally located more anterior and lateral when compared to the tibial nerve.
- v. Clinical pearls:
 1. For surgical anesthesia, identification of both nerves will provide a more consistent block.
 2. For post-operative analgesia, a single nerve stimulation $\leq 5\text{mA}$ is generally adequate
 3. Remember to block the saphenous nerve if the medial aspect of the lower limb is within the surgical site

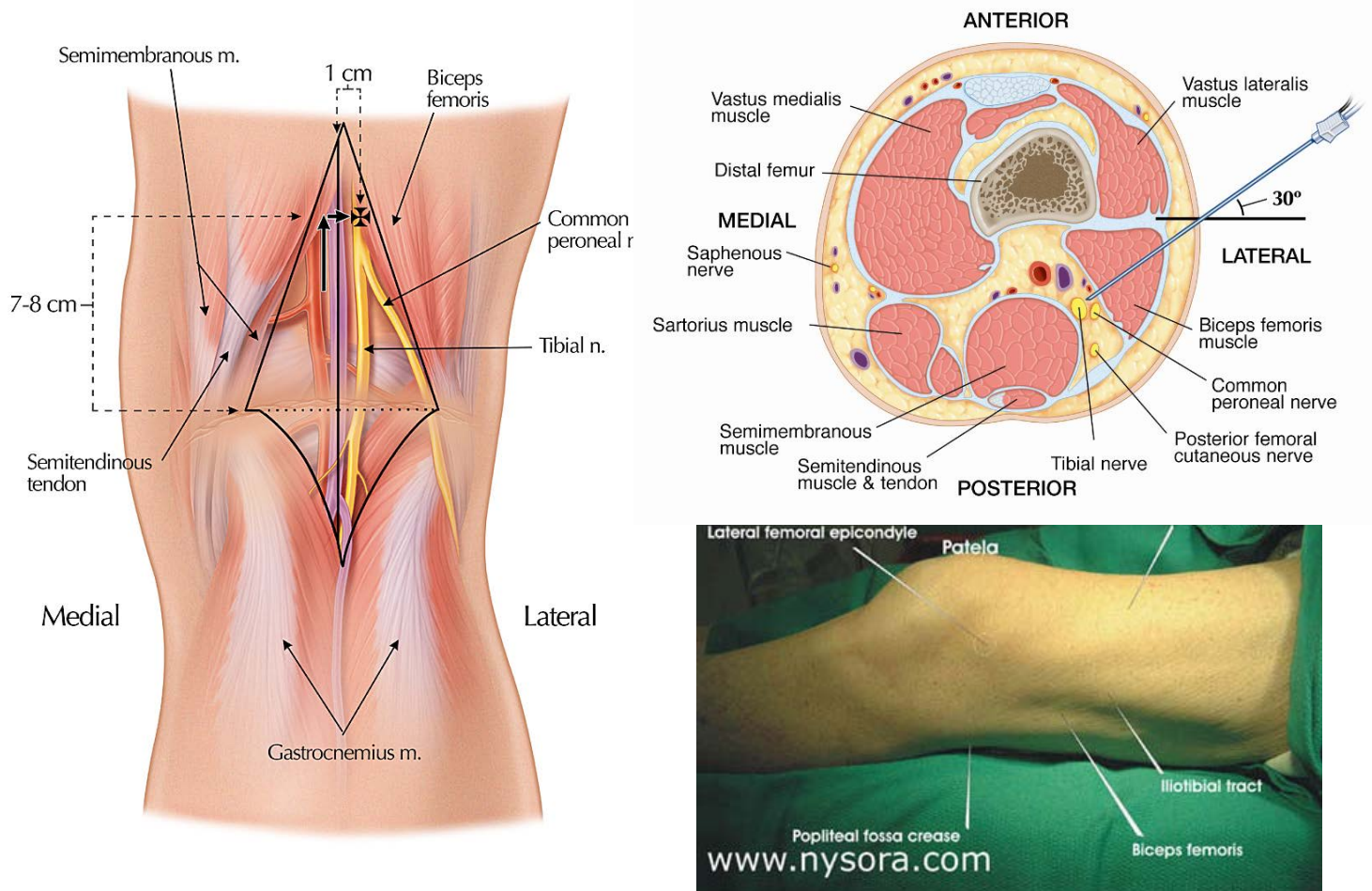


Figure 22. Landmark-based popliteal sciatic nerve blockade (posterior and lateral approaches)

2. Ultrasound-guided

- a. Scanning technique: Start with the patient prone, and orient the probe for a cross-sectional view of the neurovascular structures just above the popliteal crease. Trace nerve to see the separation and rejoining of the peroneal and tibial branches. Note that the peroneal branch is lateral and smaller, while the tibial branch is larger and medial
- b. Ideal image: The sciatic nerve should appear as a bilobar hyperechoic structure superficial and lateral to the popliteal artery. The nerve may also have separated into the tibial and peroneal divisions.
- c. Needle approach: In-plane or out-of-plane needle approach may be used

- d. Clinical pearls:
- i. In patients with a small body habitus, a high-frequency linear probe may produce adequate images. However, most patients will require imaging with a mid- or low-frequency probe.
 - ii. The sciatic nerve above the popliteal crease does not travel parallel to the skin. Therefore, maintain a slight caudad angulation of the probe for best visualization of the nerve(s).
 - iii. For an OOP approach, choose a needle insertion location just distal to the bifurcation. Since the needle will be directed proximally, and the catheter advanced even further cephalad (if applicable). Visualization of local anesthetic spread from the catheter tip often ends up occurring far more proximal than the starting position. Visualization becomes progressively more difficult as the sciatic nerve courses deeper into the extremity.

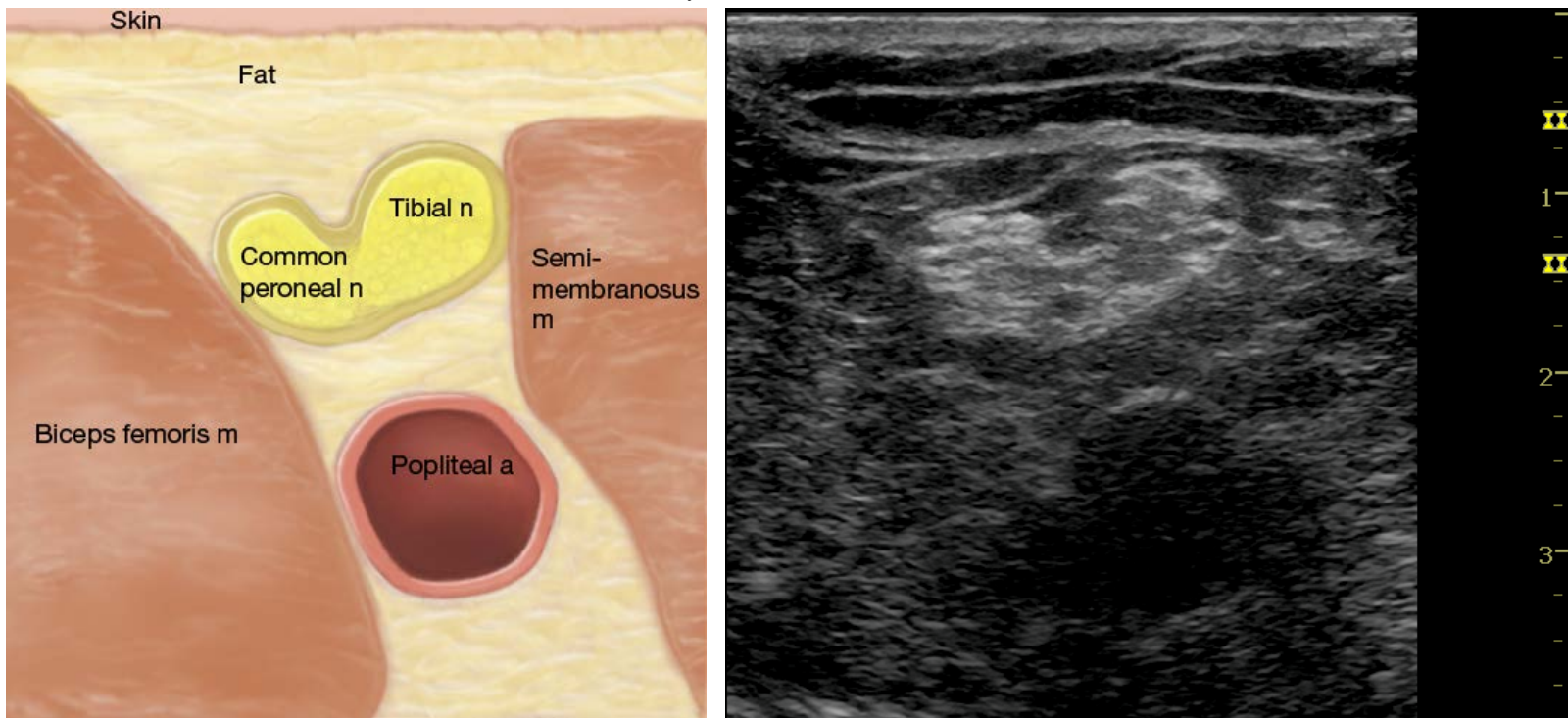


Figure 23. *Ultrasound-guided popliteal blockade (anatomic illustration and ultrasound image)*

- Complications: Local nerve injury, intravascular injection (seizure), hematoma formation, infection

F. ANKLE BLOCK

- Indication: Surgical procedures of the foot distal to the ankle
- Level of Blockade: Peripheral nerves (posterior tibial, deep peroneal, superficial peroneal, saphenous, sural) of the foot at the level of the ankle
- Limitations:
 1. Surgeries requiring high or extended lower leg tourniquet pressures
 2. Painful block if not adequately sedated
 3. Multiple injections (5) are required for complete blockade
- Surface landmarks:
 1. Medial and lateral malleoli (anteriorly, mark intermalleolar line)
 2. Achilles tendon and calcaneum
 3. Extensor hallucis longus tendons (accentuate by having patient dorsiflex against resistance)
 4. Posterior tibial artery (pulse)
- Technique:

1. **Posterior tibial nerve:** Needle insertion site at the superio-posterior border of medial malleolus; Inject 8-12 mL of local anesthetic posterior to the posterior tibial artery.
 2. **Deep peroneal nerve:** Needle insertion site is between the extensor hallucis longus and extensor digitorum longus tendon along the intermalleolar line. Inject 5 mL of local anesthetic.
 3. **Superficial peroneal nerve:** Subcutaneous injection from the point of deep peroneal n. injection to the lateral malleolus. Inject 5 mL of local anesthetic.
 4. **Saphenous nerve:** Subcutaneous injection from the point of deep peroneal n. injection to the medial malleolus. Inject 5 mL of local anesthetic.
 5. **Sural nerve:** Needle insertion site is at the superio-posterior border of lateral malleolus (lateral to Achilles tendon); Contact the lateral malleolus, withdraw slightly, and inject 6-8 mL of local anesthetic.
- **Clinical pearls:**
 1. The sural nerve is found in a more superficial position than the tibial nerve
 2. Epinephrine containing solutions should be avoided in this circumferential injection
 3. Excellent block for diabetic patients requiring amputation of the forefoot or toes
 4. Patient cooperation is not necessary, so moderate sedation may be used
 - **Complications:** Local nerve injury, intravascular injection, bleeding, and infection (all are quite rare)

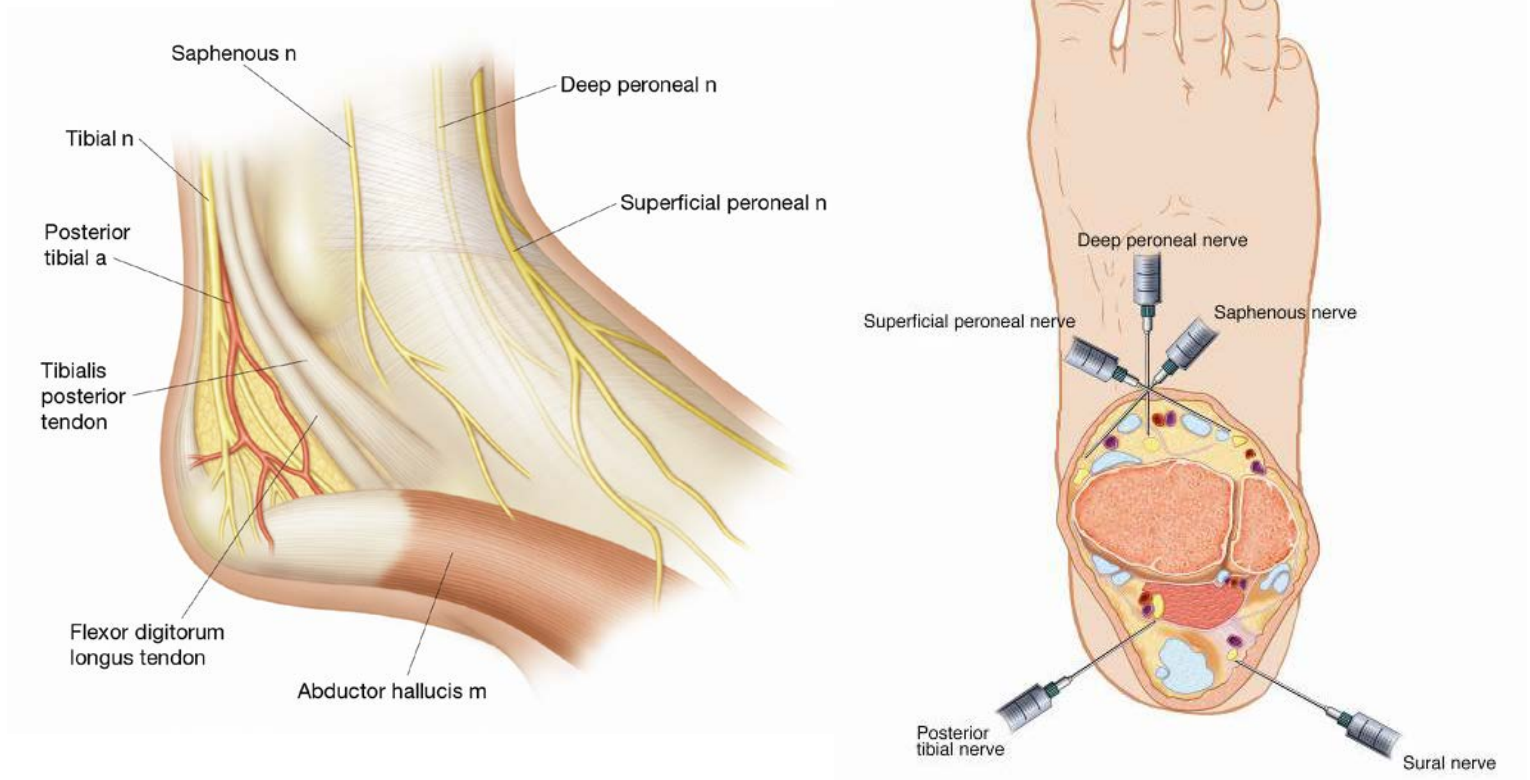


Figure 24. Landmark-based ankle blockade

V. Truncal Neuroanatomy and Regional Techniques

A. PARAVERTEBRAL BLOCKADE

- Indication:
 1. Primary anesthetic for breast surgery \pm axillary dissection, chest wall procedures, herniorrhaphy, or endovascular procedures
 2. Post-operative analgesic for video-assisted thoracoscopy, thoracotomy, minimally invasive cardiac surgery, nephrectomy, cholecystectomy, or C-section
- Level of blockade: Spinal roots of the dermatomes within the operative field
 1. Mastectomy w/ axillary dissection [T1-T6]
 2. Breast biopsy [Dermatome corresponding to biopsy site]
 3. Umbilical hernia [T9-T11]
 4. Inguinal herniorrhaphy [T10-L2]
- Limitations: Optimizing success requires *multiple* injection sites
- Landmarks:
 1. Midpoint of the most superior aspect of each spinous process to be blocked
 2. Needle entry is 2.5 cm lateral to each spinous process ipsilateral to the operative site
 - NOTE: Because of the extreme angulation of the thoracic spinous processes, this mark should overlie the transverse process of the immediately caudal vertebrae (i.e. a mark lateral to the T3 spinous process overlies the transverse process of T4)
- Technique:
 1. Landmark-based
 - a. Patient is seated upright with their neck flexed, back arched, and shoulders dropped forward
 - b. 22g short bevel needle (attached to a syringe via extension tubing) is advanced approximately 2-4 cm perpendicular to the back until it comes into contact with the transverse process of the vertebra
 - c. Needle is then advanced *caudad* to the transverse process approximately 1-cm until a loss of resistance (“pop”) is felt
 - d. Local anesthetic (4-6 mL; 10 mL for single-level breast biopsy) is then injected incrementally after negative aspiration

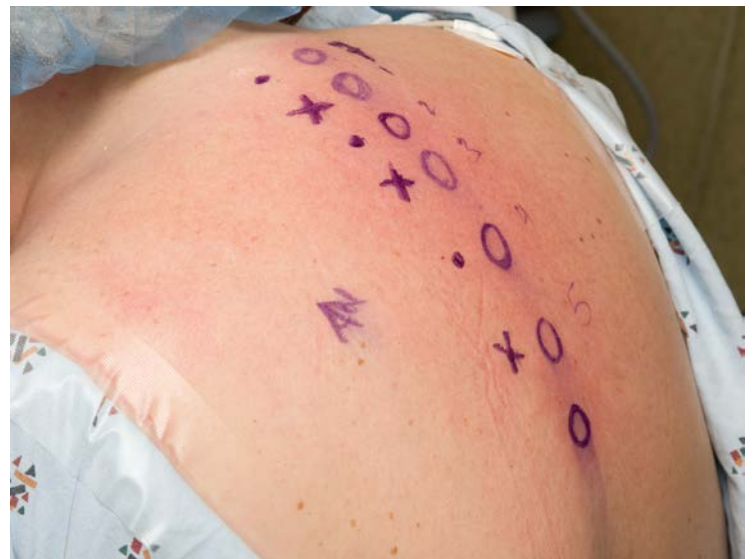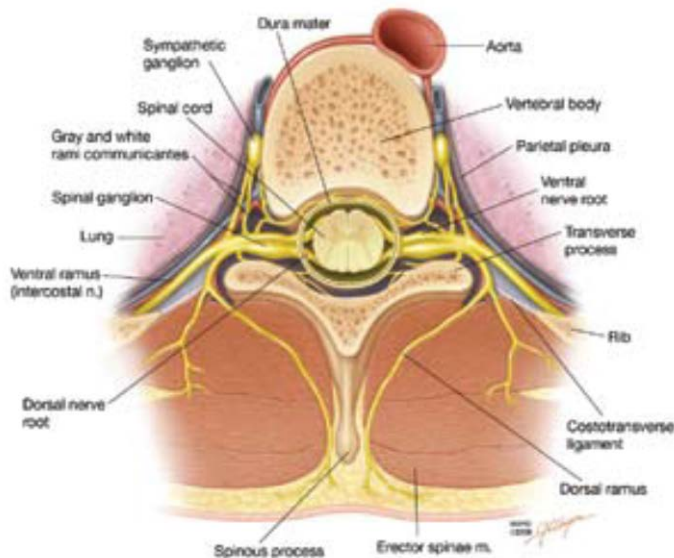


Figure 25. Landmark-based paravertebral blockade

2. Ultrasound-guided
 - a. Positioning same for landmark-based technique
 - b. Scanning technique: Start with the probe oriented parallel to the neuraxis, adjacent to the first level to be blocked. Scan medial-to-lateral to identify the transverse processes (see ultrasound image below).
 - c. Ideal image: The hyperechoic cortical surfaces of the transverse processes should be readily apparent. The paraspinal ligament and pleura should appear as

hyperechoic membranes delineating the deep and superficial limits of the paravertebral space.

- d. Needle approach: In-plane needle approach is preferred. The needle (attached to a syringe via extension tubing) is advanced until the tip is situated within the paravertebral space. Local anesthetic (4-6 mL; 10 mL for single-level breast biopsy) is then injected incrementally after negative aspiration.
- e. Clinical pearls:
 - i. It is important to take into account the steep angulation of the spinous processes in the thoracic spine when performing a paravertebral block with any technique. The transverse process that is directly lateral from a particular spinous process originates from the vertebral body one level below that of the spinous process. For example, the transverse process seen directly lateral to the T4 spinous process would be the T5 transverse process; thus, placing the needle inferior to the T5 transverse process would target the T5 spinal nerve.
 - ii. The transverse processes are deepest at the upper thoracic levels, becoming more superficial in the mid-thoracic region. This would seem to create an unfavorable angle for needle entry between transverse processes using a caudal to rostral needle approach; however, this has not been an issue in my experience. In addition, the ergonomics and hand mechanics of a caudal to rostral needle approach are significantly better than attempting a rostral to caudal technique.
 - iii. As the probe and needle insertion site are moved more laterally, the paravertebral space becomes narrower in the anterior to posterior dimension, with the pleura more closely approaching the transverse process or rib. This results in a smaller target area for the needle tip.

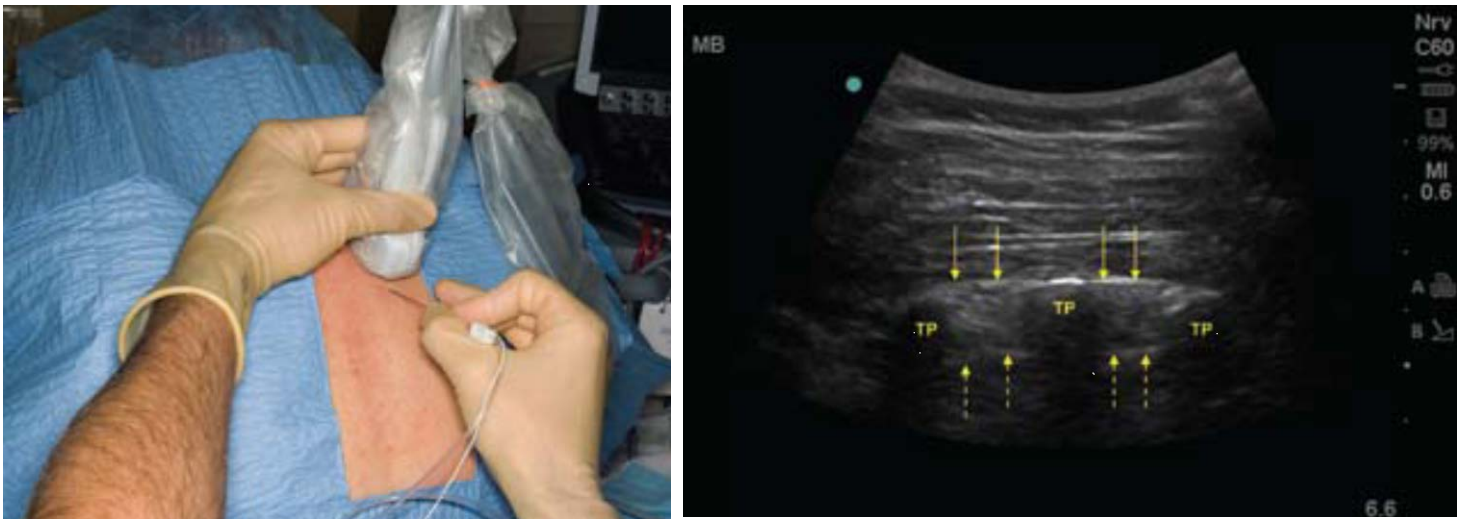

Figure 26. *Ultrasound-guided paravertebral blockade*

- Complications: Local anesthetic toxicity, pneumothorax, epidural or intrathecal spread, hypotension, vascular puncture.

B. TRANSVERSUS ABDOMINIS PLANE BLOCKADE

- Indication: Postoperative analgesia for mid and lower abdominal surgical procedure
 1. Ventral and inguinal hernia repair
 2. Laparoscopic and open appendectomy/cholecystectomy
 3. Cesarean section
 4. Abdominal hysterectomy
 5. Nephrectomy/renal transplant
 6. Laparoscopic and open colorectal surgery
- Level of blockade: Ventral branches of T10-L1 (occasional T7-T9) spinal nerves as well as ilioinguinal and iliohypogastric nerves

- Limitations:
 1. Analgesia limited to abdominal wall only (no blockade of viscera)
 2. Landmarks difficult to identify in obese patients
- Landmarks:
 1. Triangle of Petit: Iliac crest, latissimus dorsi, and external oblique
 2. Located along the mid-axillary line inferior to the lower costal margin and superior to the iliac crest
- Technique (ultrasound-guided):
 1. Supine position, arm above the head on the side to be blocked
 2. Scanning technique:
 - a. Ultrasound probe is placed, with some pressure, parallel to the iliac crest 1-2 cm superior to crest
 - b. Scan anterior to posterior to identify the posterior aponeurosis of the transversus abdominis muscle
 3. Ideal image: Three distinct muscular layers (external oblique, internal oblique, transversus abdominis) should be identified in cross section. The peritoneum and bowel peristalsis can often be noted just deep to the transversus abdominis muscle layer.
 4. Needle approach:
 - a. In-plane needle approach should be used
 - b. A 'pop' can be felt as the external oblique and internal oblique fascial planes are traversed
- Complications: Peritoneal puncture is possible, and there has been one case report of a liver hematoma in the literature secondary to a *blind* technique TAP block. Standard complications (e.g. local toxicity, infection, bleeding, etc) still apply.

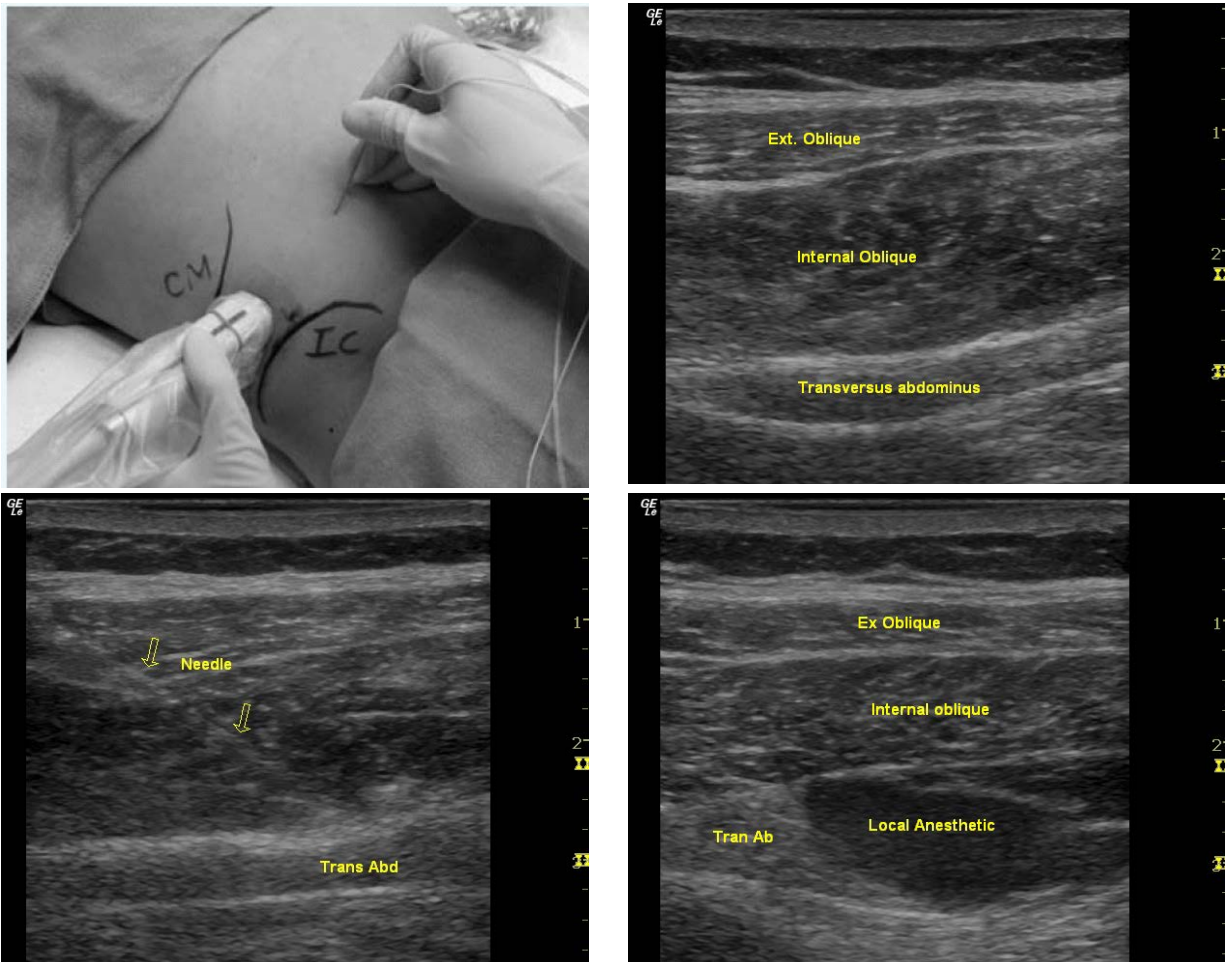


Figure 27. Ultrasound-guided transversus abdominis plane blockade

Suggested Reading

1. Winnie AP, Ramamurthy S, Durrani Z, Radonjic R: Interscalene cervical plexus block: a single-injection technic. *Anesth Analg* 1975; 54: 370-5
2. Wong GY, Brown DL, Miller GM, Cahill DR: Defining the cross-sectional anatomy important to interscalene brachial plexus block with magnetic resonance imaging. *Reg Anesth Pain Med* 1998; 23: 77-80
3. Roch JJ, Sharrock NE, Neudachin L: Interscalene brachial plexus block for shoulder surgery: a proximal paresthesia is effective. *Anesth Analg* 1992; 75: 386-8
4. Silverstein WB, Saiyed MU, Brown AR: Interscalene block with a nerve stimulator: a deltoid motor response is a satisfactory endpoint for successful block. *Reg Anesth Pain Med* 2000; 25: 356-9
5. Mulroy M: *Regional Anesthesia: An Illustrated Procedural Guide*. New York, Little, Brown, & Co., 1996
6. Pham-Dang C, Gunst JP, Gouin F, Poirier P, Touchais S, Meunier JF, Kick O, Drouet JC, Bourreli B, Pinaud M: A novel supraclavicular approach to brachial plexus block. *Anesth Analg* 1997; 85: 111-6
7. Brown DL, Cahill DR, Bridenbaugh LD: Supraclavicular nerve block: anatomic analysis of a method to prevent pneumothorax. *Anesth Analg* 1993; 76: 530-4
8. VadeBoncouer TR WG: Supraclavicular brachial plexus anesthesia using the plumb bob method. *Techniques in Regional Anesthesia & Pain Management* 1997; 1: 151-6
9. Wedel D: *Orthopedic Anesthesia*. New York, Churchill Livingstone, 1993
10. Neal JM, Moore JM, Kopacz DJ, Liu SS, Kramer DJ, Plorde JJ: Quantitative analysis of respiratory, motor, and sensory function after supraclavicular block. *Anesth Analg* 1998; 86: 1239-44
11. Raj PP, Montgomery SJ, Nettles D, Jenkins MT: Infraclavicular brachial plexus block--a new approach. *Anesth Analg* 1973; 52: 897-904
12. Whiffler K: Coracoid block--a safe and easy technique. *Br J Anaesth* 1981; 53: 845-8
13. Sims JK: A modification of landmarks for infraclavicular approach to brachial plexus block. *Anesth Analg* 1977; 56: 554-5
14. Salazar CH, Espinosa W: Infraclavicular brachial plexus block: variation in approach and results in 360 cases. *Reg Anesth Pain Med* 1999; 24: 411-6
15. Wilson JL, Brown DL, Wong GY, Ehman RL, Cahill DR: Infraclavicular brachial plexus block: parasagittal anatomy important to the coracoid technique. *Anesth Analg* 1998; 87: 870-3
16. Urmey W: *Upper extremity blocks*. Philadelphia, W.B. Saunders, 1996
17. Pollock J: *Regional Anesthesia for hand surgery*. *Techniques in Regional Anesthesia & Pain Management* 1999; 3: 79-84
18. Baranowski AP, Pither CE: A comparison of three methods of axillary brachial plexus anaesthesia. *Anaesthesia* 1990; 45: 362-5
19. Schroeder LE, Horlocker TT, Schroeder DR: The efficacy of axillary block for surgical procedures about the elbow. *Anesth Analg* 1996; 83: 747-51
20. Cockings E MP, Lewis RC.: Transarterial brachial plexus blockade using high doses of 1.5% mepivacaine. *Reg Anesth* 1987; 12: 159-64
21. Yamamoto K, Tsubokawa T, Shibata K, Kobayashi T: Area of paresthesia as determinant of sensory block in axillary brachial plexus block. *Reg Anesth* 1995; 20: 493-7
22. Bouaziz H, Narchi P, Mercier FJ, Labaille T, Zerrouk N, Girod J, Benhamou D: Comparison between conventional axillary block and a new approach at the midhumeral level. *Anesth Analg* 1997; 84: 1058-62
23. Montgomery SJ PP, Nettles D, Jenkins MT: The use of the nerve stimulator with standard unsheathed needles in nerve blockade. *Anesth Analg* 1973; 52: 827-31
24. Coventry DM, Barker KF, Thomson M: Comparison of two neurostimulation techniques for axillary brachial plexus blockade. *Br J Anaesth* 2001; 86: 80-3
25. Sia S, Lepri A, Ponzeccchi P: Axillary brachial plexus block using peripheral nerve stimulator: a comparison between double- and triple-injection techniques. *Reg Anesth Pain Med* 2001; 26: 499-503
26. Thompson G: The multiple compartment approach to brachial plexus anesthesia. *Techniques in Regional Anesthesia & Pain Management* 1997; 1: 163-8
27. B. Braun Medical IDoME, 1994
28. Coveney E, Weltz CR, Greengrass R, Iglehart JD, Leight GS, Steele SM, Lyerly HK: Use of paravertebral block anesthesia in the surgical management of breast cancer: experience in 156 cases. *Ann Surg* 1998; 227: 496-501

29. Greengrass R, Buckenmaier CC, 3rd: Paravertebral anaesthesia/analgesia for ambulatory surgery. *Best Pract Res Clin Anaesthesiol* 2002; 16: 271-83
30. Hadzic A VJ: Thoracic paravertebral block. *The Internet Journal of Anesthesiology* 2002; 5
31. Klein SM, Steele SM, Greengrass R: A clinical overview of paravertebral blockade. *The Internet Journal of Anesthesiology* 1999; 3
32. Terheggen MA, Wille F, Borel Rinkes IH, Ionescu TI, Knappe JT: Paravertebral blockade for minor breast surgery. *Anesth Analg* 2002; 94: 355-9, table of contents
33. Canto M, Sanchez MJ, Casas MA, Bataller ML: Bilateral paravertebral blockade for conventional cardiac surgery. *Anaesthesia* 2003; 58: 365-70
34. Lonnqvist PA, Olsson GL: Paravertebral vs epidural block in children. Effects on postoperative morphine requirement after renal surgery. *Acta Anaesthesiol Scand* 1994; 38: 346-9
35. Bigler D, Dirkes W, Hansen R, Rosenberg J, Kehlet H: Effects of thoracic paravertebral block with bupivacaine versus combined thoracic epidural block with bupivacaine and morphine on pain and pulmonary function after cholecystectomy. *Acta Anaesthesiol Scand* 1989; 33: 561-4
36. Naja MZ, Ziade MF, Lonnqvist PA: General anaesthesia combined with bilateral paravertebral blockade (T5-6) vs. general anaesthesia for laparoscopic cholecystectomy: a prospective, randomized clinical trial. *Eur J Anaesthesiol* 2004; 21: 489-95
37. Lonnqvist PA, MacKenzie J, Soni AK, Conacher ID: Paravertebral blockade. Failure rate and complications. *Anaesthesia* 1995; 50: 813-5
38. Lemay E, Guay J, Cote C, Boivin MC, Varin F: The number of injections does not influence local anesthetic absorption after paravertebral blockade. *Can J Anaesth* 2003; 50: 562-7
39. Brown DL: Lower extremity anatomy., *Atlas of Regional Anesthesia*, 2nd Edition. Edited by In. Brown DL, ed. Philadelphia, PA, W.B. Saunders Company, 1999, pp 75-84
40. Farny J, Girard M, Drolet P: Posterior approach to the lumbar plexus combined with a sciatic nerve block using lidocaine. *Can J Anaesth* 1994; 41: 486-91
41. Capdevila X, Macaire P, Dadure C, Choquet O, Biboulet P, Ryckwaert Y, D'Athis F: Continuous psoas compartment block for postoperative analgesia after total hip arthroplasty: new landmarks, technical guidelines, and clinical evaluation. *Anesth Analg* 2002; 94: 1606-13, table of contents
42. Chudinov A, Berkenstadt H, Salai M, Cahana A, Perel A: Continuous psoas compartment block for anaesthesia and perioperative analgesia in patients with hip fractures. *Reg Anesth Pain Med* 1999; 24: 563-8
43. Brown DL: Psoas compartment block, *Atlas of Regional Anesthesia*, 2nd Edition. Edited by Brown DL. Philadelphia, PA, W.B. Saunders Company, 1999, pp 88-91
44. Chayen D, Nathan H, Chayen M: The psoas compartment block. *Anesthesiology* 1976; 45: 95-9
45. Parkinson SK, Mueller JB, Little WL, Bailey SL: Extent of blockade with various approaches to the lumbar plexus. *Anesth Analg* 1989; 68: 243-8
46. Stevens RD, Van Gessel E, Flory N, Fournier R, Gamulin Z: Lumbar plexus block reduces pain and blood loss associated with total hip arthroplasty. *Anesthesiology* 2000; 93: 115-21
47. Klein SM, D'Ercole F, Greengrass RA, Warner DS: Enoxaparin associated with psoas hematoma and lumbar plexopathy after lumbar plexus block. *Anesthesiology* 1997; 87: 1576-9
48. Weller RS, Gerancher JC, Crews JC, Wade KL: Extensive retroperitoneal hematoma without neurologic deficit in two patients who underwent lumbar plexus block and were later anticoagulated. *Anesthesiology* 2003; 98: 581-5
49. Winnie AP: Regional anesthesia. *Surg Clin North Am* 1975; 55: 861-92
50. Lennon RL, Horlocker TT: *Mayo Clinic Analgesic Pathway: Peripheral Nerve Blockade for Major Orthopedic Surgery*. Boca Raton, FL, Mayo Clinic Scientific Press, Taylor & Francis Group, 2006
51. Labat G: *Regional Anesthesia: Its technic and clinical application*. Philadelphia, PA, W.B. Saunders Company, 1922
52. Winnie AP, Ramamurthy S, Durrani Z: The inguinal paravascular technic of lumbar plexus anesthesia: the "3-in-1 block". *Anesth Analg* 1973; 52: 989-96
53. Vloka JD, Hadzic A, Drobnik L, Ernest A, Reiss W, Thys DM: Anatomical landmarks for femoral nerve block: a comparison of four needle insertion sites. *Anesth Analg* 1999; 89: 1467-70
54. Lang SA, Yip RW, Chang PC, Gerard MA: The femoral 3-in-1 block revisited. *J Clin Anesth* 1993; 5: 292-6
55. Capdevila X, Biboulet P, Bouregba M, Rubenovitch J, Jaber S: Bilateral continuous 3-in-1 nerve blockade for postoperative pain relief after bilateral femoral shaft surgery. *J Clin Anesth* 1998; 10: 606-9
56. Seeberger MD, Urwyler A: Paravascular lumbar plexus block: block extension after femoral nerve stimulation and injection of 20 vs. 40 ml mepivacaine 10 mg/ml. *Acta Anaesthesiol Scand* 1995; 39: 769-73

57. Vloka JD HA, Drobnik L, Koorn R, Sanborn K, Thy DM.: Femoral nerve block: The sartorius muscle twitch can be used as a reliable guide to obtain a quadriceps muscle response. *Anesthesiology* 1998; 89: A861
58. Brown D: *Regional Anesthesia and Analgesia*, 1st Edition. Philadelphia, PA, W.B. Saunders Company, 1996
59. Dalens B, Vanneville G, Tanguy A: Comparison of the fascia iliaca compartment block with the 3-in-1 block in children. *Anesth Analg* 1989; 69: 705-13
60. Dahl JB, Christiansen CL, Daugaard JJ, Schultz P, Carlsson P: Continuous blockade of the lumbar plexus after knee surgery--postoperative analgesia and bupivacaine plasma concentrations. A controlled clinical trial. *Anaesthesia* 1988; 43: 1015-8
61. Ganapathy S, Wasserman RA, Watson JT, Bennett J, Armstrong KP, Stockall CA, Chess DG, MacDonald C: Modified continuous femoral three-in-one block for postoperative pain after total knee arthroplasty. *Anesth Analg* 1999; 89: 1197-202
62. Serpell MG, Millar FA, Thomson MF: Comparison of lumbar plexus block versus conventional opioid analgesia after total knee replacement. *Anaesthesia* 1991; 46: 275-7
63. Capdevila X, Biboulet P, Bouregba M, Barthelet Y, Rubenovitch J, d'Athis F: Comparison of the three-in-one and fascia iliaca compartment blocks in adults: clinical and radiographic analysis. *Anesth Analg* 1998; 86: 1039-44
64. Morau D, Lopez S, Biboulet P, Bernard N, Amar J, Capdevila X: Comparison of continuous 3-in-1 and fascia Iliaca compartment blocks for postoperative analgesia: feasibility, catheter migration, distribution of sensory block, and analgesic efficacy. *Reg Anesth Pain Med* 2003; 28: 309-14
65. Atchabahian A, Brown AR: Postoperative neuropathy following fascia iliaca compartment blockade. *Anesthesiology* 2001; 94: 534-6
66. Jochum D, Iohom G, Choquet O, Macalou D, Ouologuem S, Meuret P, Kayembe F, Heck M, Mertes PM, Bouaziz H: Adding a selective obturator nerve block to the parasacral sciatic nerve block: an evaluation. *Anesth Analg* 2004; 99: 1544-9; table of contents
67. McNamee DA, Parks L, Milligan KR: Postoperative analgesia following total knee replacement: an evaluation of the addition of an obturator nerve block to combined femoral and sciatic nerve block. *Acta Anaesthesiol Scand* 2002; 46: 95-99
68. Macalou D, Trueck S, Meuret P, Heck M, Vial F, Ouologuem S, Capdevila X, Virion JM, Bouaziz H: Postoperative analgesia after total knee replacement: the effect of an obturator nerve block added to the femoral 3-in-1 nerve block. *Anesth Analg* 2004; 99: 251-4
69. Atanassoff PG, Weiss BM, Brull SJ, Horst A, Kulling D, Stein R, Theiler I: Electromyographic comparison of obturator nerve block to three-in-one block. *Anesth Analg* 1995; 81: 529-33
70. Atanassoff PG, Weiss BM, Brull SJ: Lidocaine plasma levels following two techniques of obturator nerve block. *J Clin Anesth* 1996; 8: 535-9
71. Akata T, Murakami J, Yoshinaga A: Life-threatening haemorrhage following obturator artery injury during transurethral bladder surgery: a sequel of an unsuccessful obturator nerve block. *Acta Anaesthesiol Scand* 1999; 43: 784-8
72. Hong Y, O'Grady T, Lopresti D, Carlsson C: Diagnostic obturator nerve block for inguinal and back pain: a recovered opinion. *Pain* 1996; 67: 507-509
73. Wassef MR: Interadductor approach to obturator nerve blockade for spastic conditions of adductor thigh muscles. *Reg Anesth* 1993; 18: 13-7
74. Bridenbaugh PO, Wedel DJ: *The Lower Extremity: Somatic Blockade, Neural Blockade in Clinical Anesthesia and Management of Pain*, 3rd Edition. Edited by Bridenbaugh PO, Cousins MJ. Philadelphia, Lippincott-Raven, 1998
75. Moore DC: *Regional Blockade*, 4th Edition. Springfield, IL, Charles C. Thomas, 1963
76. McQuillan PM: *Obturator Nerve, Regional Anesthesia Atlas of Anatomy and Techniques*. Edited by Hanhn MB, McQuillan PM, Sheplock GJ. New York, Mosby, 1996
77. Cook P, Stevens J, Gaudron C: Comparing the effects of femoral nerve block versus femoral and sciatic nerve block on pain and opiate consumption after total knee arthroplasty. *J Arthroplasty* 2003; 18: 583-6
78. Weber A, Fournier R, Van Gessel E, Gamulin Z: Sciatic nerve block and the improvement of femoral nerve block analgesia after total knee replacement. *Eur J Anaesthesiol* 2002; 19: 834-6
79. Bailey SL, Parkinson SK, Little WL, Simmerman SR: Sciatic nerve block. A comparison of single versus double injection technique. *Reg Anesth* 1994; 19: 9-13
80. Manani G, Angel A, Civran E, Tegazzin V, Dal Vecchio AD, Giron GP: Sciatic nerve block by the anterior and posterior approach for operations on the lower extremity. A comparative study. *Acta Anaesthesiol Belg* 1982; 33: 183-93

81. Buckenmaier CC, 3rd, Xenos JS, Nilsen SM: Lumbar plexus block with perineural catheter and sciatic nerve block for total hip arthroplasty. *J Arthroplasty* 2002; 17: 499-502
82. Luber MJ, Greengrass R, Vail TP: Patient satisfaction and effectiveness of lumbar plexus and sciatic nerve block for total knee arthroplasty. *J Arthroplasty* 2001; 16: 17-21
83. Taboada M, Rodriguez J, J AL, Cortes J, Gude F, Atanassoff PG: Sciatic nerve block via posterior Labat approach is more efficient than lateral popliteal approach using a double-injection technique: a prospective, randomized comparison. *Anesthesiology* 2004; 101: 138-42
84. Sukhani R, Candido KD, Doty R, Jr., Yaghmour E, McCarthy RJ: Infragluteal-parabiceps sciatic nerve block: an evaluation of a novel approach using a single-injection technique. *Anesth Analg* 2003; 96: 868-73, table of contents
85. Rucci FS, Trafficante FG, Moresi M: A new approach to sciatic nerve block in the gluteal region. *Eur J Anaesthesiol* 1989; 6: 363-71
86. Di Benedetto P, Bertini L, Casati A, Borghi B, Albertin A, Fanelli G: A new posterior approach to the sciatic nerve block: a prospective, randomized comparison with the classic posterior approach. *Anesth Analg* 2001; 93: 1040-4
87. Di Benedetto P, Casati A, Bertini L, Fanelli G: Posterior subgluteal approach to block the sciatic nerve: description of the technique and initial clinical experiences. *Eur J Anaesthesiol* 2002; 19: 682-6
88. Morris GF, Lang SA, Dust WN, Van der Wal M: The parasacral sciatic nerve block. *Reg Anesth* 1997; 22: 223-8
89. Cuvillon P, Ripart J, Jeannes P, Mahamat A, Boisson C, L'Hermite J, Vernes E, de la Coussaye JE: Comparison of the parasacral approach and the posterior approach, with single- and double-injection techniques, to block the sciatic nerve. *Anesthesiology* 2003; 98: 1436-41
90. Ho AM, Karmakar MK: Combined paravertebral lumbar plexus and parasacral sciatic nerve block for reduction of hip fracture in a patient with severe aortic stenosis. *Can J Anaesth* 2002; 49: 946-50
91. Beck GP: Anterior approach to sciatic nerve block. *Anesthesiology* 1963; 24: 222-4
92. Chelly JE, Delaunay L: A new anterior approach to the sciatic nerve block. *Anesthesiology* 1999; 91: 1655-60
93. Ericksen ML, Swenson JD, Pace NL: The anatomic relationship of the sciatic nerve to the lesser trochanter: implications for anterior sciatic nerve block. *Anesth Analg* 2002; 95: 1071-4, table of contents
94. Van Elstraete AC, Poey C, Lebrun T, Pastureau F: New landmarks for the anterior approach to the sciatic nerve block: imaging and clinical study. *Anesth Analg* 2002; 95: 214-8, table of contents
95. Barbero C, Fuzier R, Samii K: Anterior approach to the sciatic nerve block: adaptation to the patient's height. *Anesth Analg* 2004; 98: 1785-8, table of contents
96. Pham Dang C: Midfemoral block: a new lateral approach to the sciatic nerve. *Anesth Analg* 1999; 88: 1426
97. Brown DL: *Atlas of Regional Anesthesia*, 2nd Edition. Philadelphia, PA, W.B. Saunders Company, 1999
98. Vloka JD, Hadzic A, April E, Thys DM: Anterior approach to the sciatic nerve block: the effects of leg rotation. *Anesth Analg* 2001; 92: 460-2
99. Moore CS, Sheppard D, Wildsmith JA: Thigh rotation and the anterior approach to the sciatic nerve: a magnetic resonance imaging study. *Reg Anesth Pain Med* 2004; 29: 32-5
100. Bonner SM, Pridie AK: Sciatic nerve palsy following uneventful sciatic nerve block. *Anaesthesia* 1997; 52: 1205-7
101. Sala-Blanch X, Pomes J, Matute P, Valls-Sole J, Carrera A, Tomas X, Garcia-Diez AI: Intra-neural injection during anterior approach for sciatic nerve block. *Anesthesiology* 2004; 101: 1027-30
102. Hadzic A, Vloka JD: A comparison of the posterior versus lateral approaches to the block of the sciatic nerve in the popliteal fossa. *Anesthesiology* 1998; 88: 1480-6
103. McLeod DH, Wong DH, Claridge RJ, Merrick PM: Lateral popliteal sciatic nerve block compared with subcutaneous infiltration for analgesia following foot surgery. *Can J Anaesth* 1994; 41: 673-6
104. McLeod DH, Wong DH, Vaghadia H, Claridge RJ, Merrick PM: Lateral popliteal sciatic nerve block compared with ankle block for analgesia following foot surgery. *Can J Anaesth* 1995; 42: 765-9
105. Zetlaoui PJ, Bouaziz H: Lateral approach to the sciatic nerve in the popliteal fossa. *Anesth Analg* 1998; 87: 79-82
106. Schurman DJ: Ankle-block anesthesia for foot surgery. *Anesthesiology* 1976; 44: 348-52
107. Netter FH: *Atlas of Human Anatomy*. 3rd ed. Summit, New Jersey, Ciba-Geigy, 1990
108. Barrington MJ, et al: Spread of injectate after ultrasound-guided subcostal transversus abdominis plane block: a cadaveric study. *Anaesthesia*, 2009. 64(7): 745-50.
109. Belavy D, et al: Ultrasound-guided transversus abdominis plane block for analgesia after Caesarean delivery. *Br J Anaesth*, 2009. 103(5): 726-30.

110. Bonnet F, Berger J, Aveline C: Transversus abdominis plane block: what is its role in postoperative analgesia? *Br J Anaesth*, 2009. 103(4): 468-70.
111. Carney J, et al: The transversus abdominis plane block provides effective postoperative analgesia in patients undergoing total abdominal hysterectomy. *Anesth Analg*, 2008. 107(6): 2056-60.
112. Cowlshaw P, Belavy D: Transversus abdominis plane block for neuropathic pain. *Reg Anesth Pain Med*, 2009. 34(2): 183.
113. El-Dawlatly AA et al: Ultrasound-guided transversus abdominis plane block: description of a new technique and comparison with conventional systemic analgesia during laparoscopic cholecystectomy. *Br J Anaesth*, 2009. 102(6): 763-7.
114. Farooq M, Carey M: A case of liver trauma with a blunt regional anesthesia needle while performing transversus abdominis plane block. *Reg Anesth Pain Med*, 2008. 33(3): 274-5.
115. Fredrickson M, Seal P, Houghton J: Early experience with the transversus abdominis plane block in children. *Paediatr Anaesth*, 2008. 18(9): 891-2.
116. Fredrickson MJ, Seal P: Ultrasound-guided transversus abdominis plane block for neonatal abdominal surgery. *Anaesth Intensive Care*, 2009. 37(3): 469-72.
117. Hebbard P et al: Ultrasound-guided transversus abdominis plane (TAP) block. *Anaesth Intensive Care*, 2007. 35(4): 616-7.
118. Jankovic ZB et al: Transversus abdominis plane block: how safe is it? *Anesth Analg*, 2008. 107(5): 1758-9.
119. Jankovic ZB, du Feu FM, McConnell P: An anatomical study of the transversus abdominis plane block: location of the lumbar triangle of Petit and adjacent nerves. *Anesth Analg*, 2009. 109(3): 981-5.
120. Jankovic ZB, Pollard SG, Nachiappan MM: Continuous transversus abdominis plane block for renal transplant recipients. *Anesth Analg*, 2009. 109(5): 1710-1.
121. Kato N et al: Serum concentration of lidocaine after transversus abdominis plane block. *J Anesth*, 2009. 23(2): 298-300.
122. McDonnell JG et al: Transversus abdominis plane block: a cadaveric and radiological evaluation. *Reg Anesth Pain Med*, 2007. 32(5): 399-404.
123. Mukhtar K, Singh S: Transversus abdominis plane block for laparoscopic surgery. *Br J Anaesth*, 2009. 102(1): 143-4.
124. Niraj G, Kelkar A, Fox AJ: Oblique sub-costal transversus abdominis plane (TAP) catheters: an alternative to epidural analgesia after upper abdominal surgery. *Anaesthesia*, 2009. 64(10): 1137-40.
125. Niraj G et al: Analgesic efficacy of ultrasound-guided transversus abdominis plane block in patients undergoing open appendicectomy. *Br J Anaesth*, 2009. 103(4): 601-5.
126. Suresh S Chan VW: Ultrasound guided transversus abdominis plane block in infants, children and adolescents: a simple procedural guidance for their performance. *Paediatr Anaesth*, 2009. 19(4): 296-9.
127. Tran TM et al: Determination of spread of injectate after ultrasound-guided transversus abdominis plane block: a cadaveric study. *Br J Anaesth* 2009; 102(1): 123-7.
128. Richardson J, Lonnqvist PA: Thoracic paravertebral block. *Br J Anaesth* 1998; 81:230-8.
129. Eid H: Paravertebral block: An overview. *Cur Anaesth Crit Care* 2009;20:65-70.
130. Karmakar M: Thoracic paravertebral block. *Anesthesiology* 2001; 95:771-80.
131. Davies RG, Myles PS, Graham JM: A comparison of the analgesic efficacy and side effects of paravertebral vs epidural blockade for thoracotomy – A systematic review and meta-analysis of randomized trials. *Br J Anaesth* 2006; 96(4):418-26.
132. Naja Z, Lonnqvist PA: Somatic paravertebral nerve blockade. Incidence of failed block and complications. *Anaesth* 2001; 56:1181-1201.
133. Iohom G, Abdalla H, O'Brien J, et al: The associations between severity of early postoperative pain, chronic postsurgical pain and plasma concentration of stable nitric oxide products after breast surgery. *Anesth Analg* 2006; 103:995-1000.
134. Kairaluoma PH, Bachmann MS, Rosenberg PH, Pere PJ: Preincisional paravertebral block reduces the prevalence of chronic pain after breast surgery. *Anesth Analg* 2006; 103:703-8.
135. Exadaktylos AK, Buggy DJ, et al: Can anesthetic technique for primary breast cancer surgery affect recurrence or metastasis? *Anesthesiology* 2006; 105:660-4.
136. Pusch F, Wildling E, Klimscha W, Weinstabl C: Sonographic measurement of needle insertion depth in paravertebral blocks in women. *Br J Anaesth* 2000; 85(6):841-3.
137. Jamieson BD, Mariano ER: Thoracic and lumbar paravertebral blocks for outpatient lithotripsy. *J Clin Anesth* 2007; 19(2):149-151.
138. Hara K et al: Ultrasound guided thoracic paravertebral block in breast surgery. *Anaesth* 2009; 64:223-5.
138. Niesen AD: How I Do It: Ultrasound-Guided Thoracic Paravertebral block. *ASRA Newsletter*, Nov 2009; 14-6.

Notes